

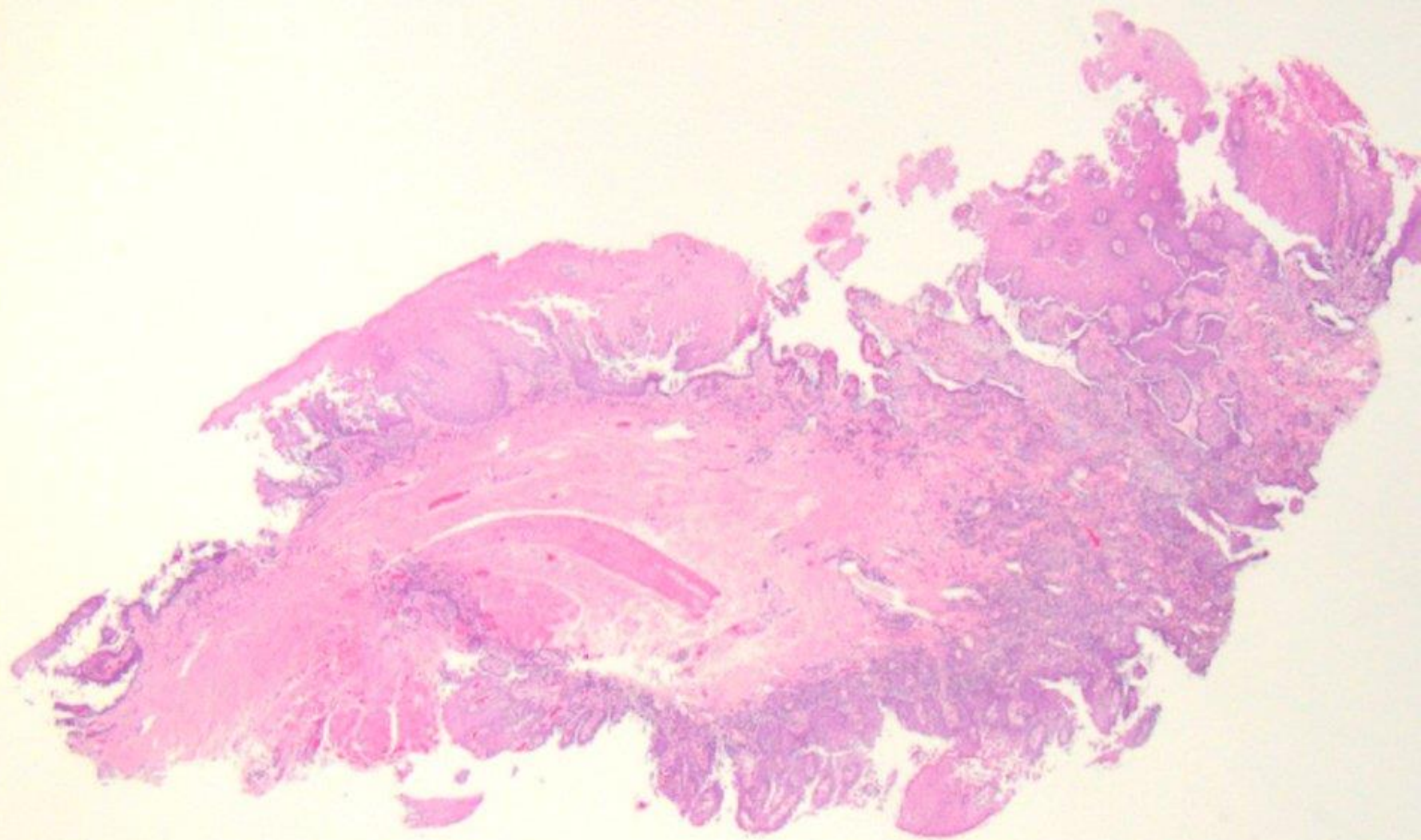
Oral Histopathology

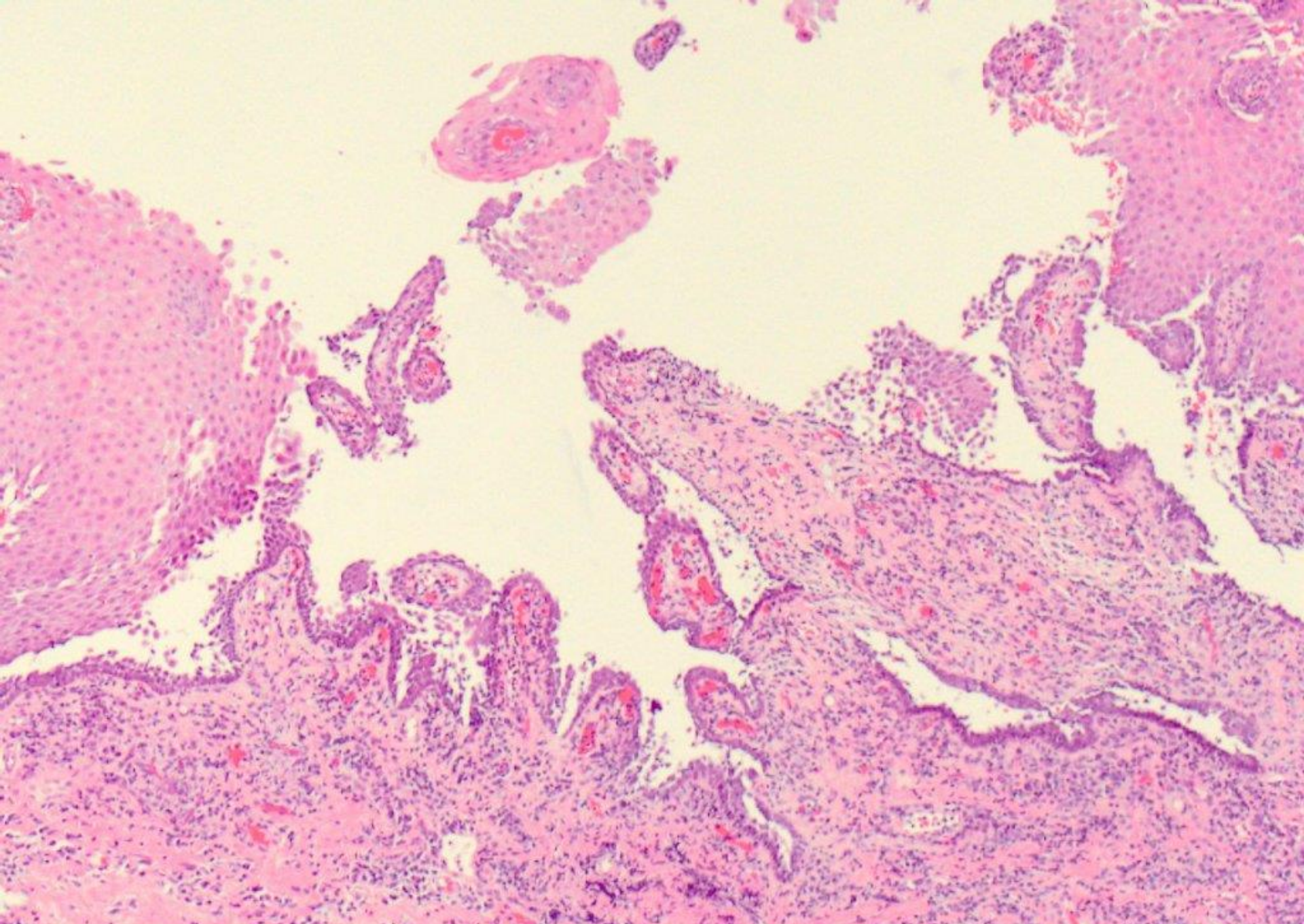
Series 27

DAVID E. KLINGMAN, DMD

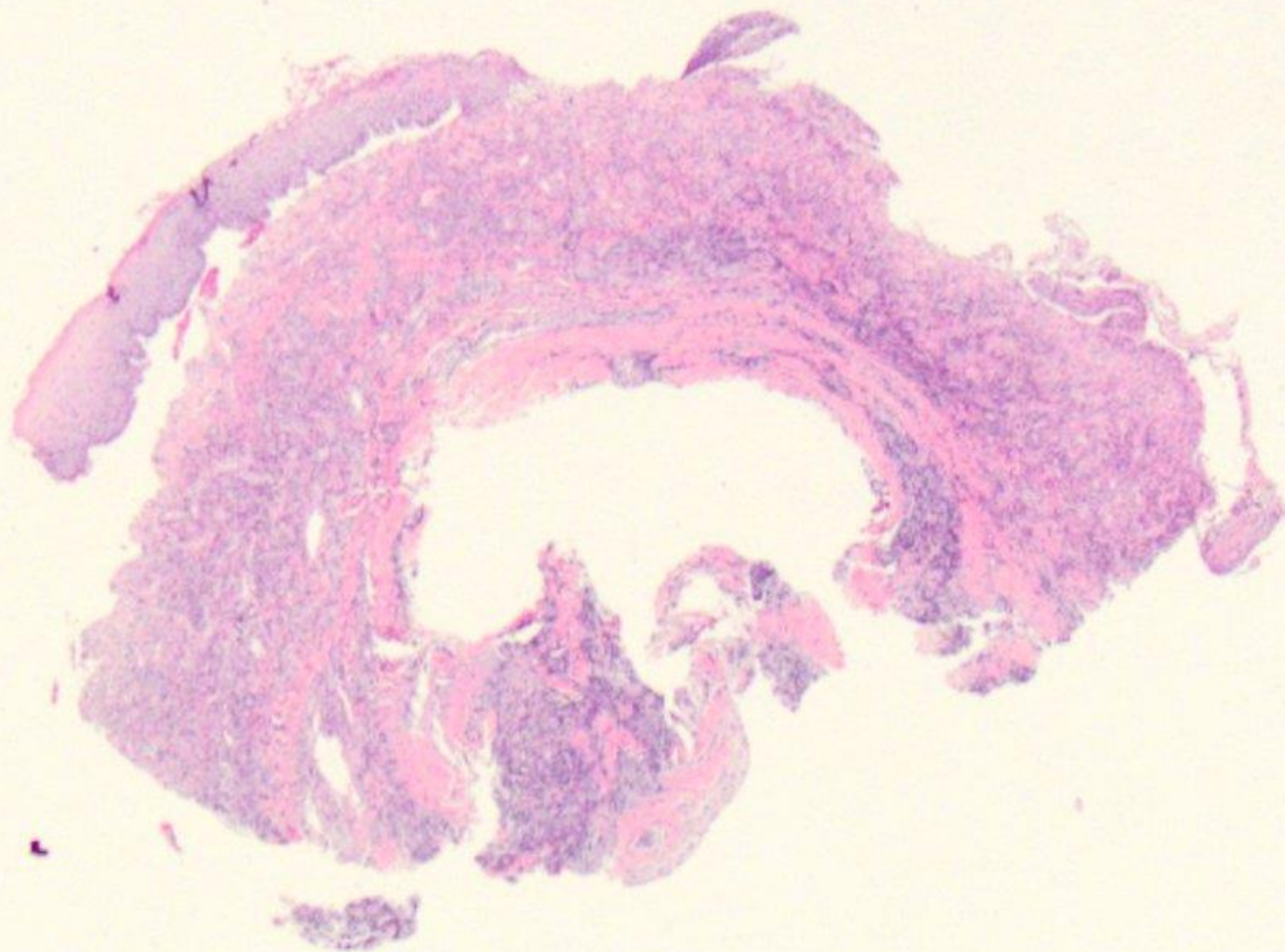
Diplomate, American Board of Oral and Maxillofacial Pathology

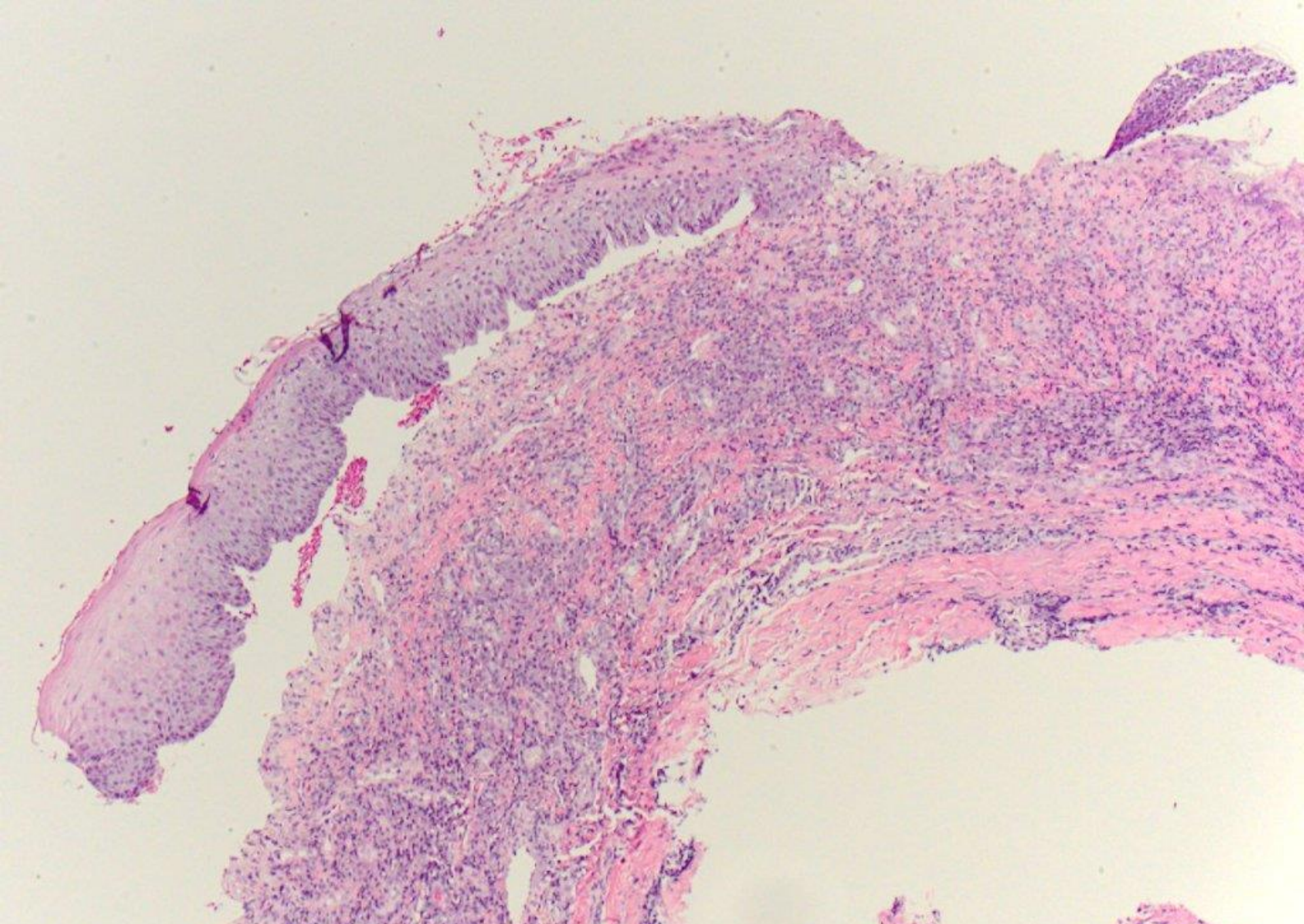
Diplomate, American Board of General Dentistry



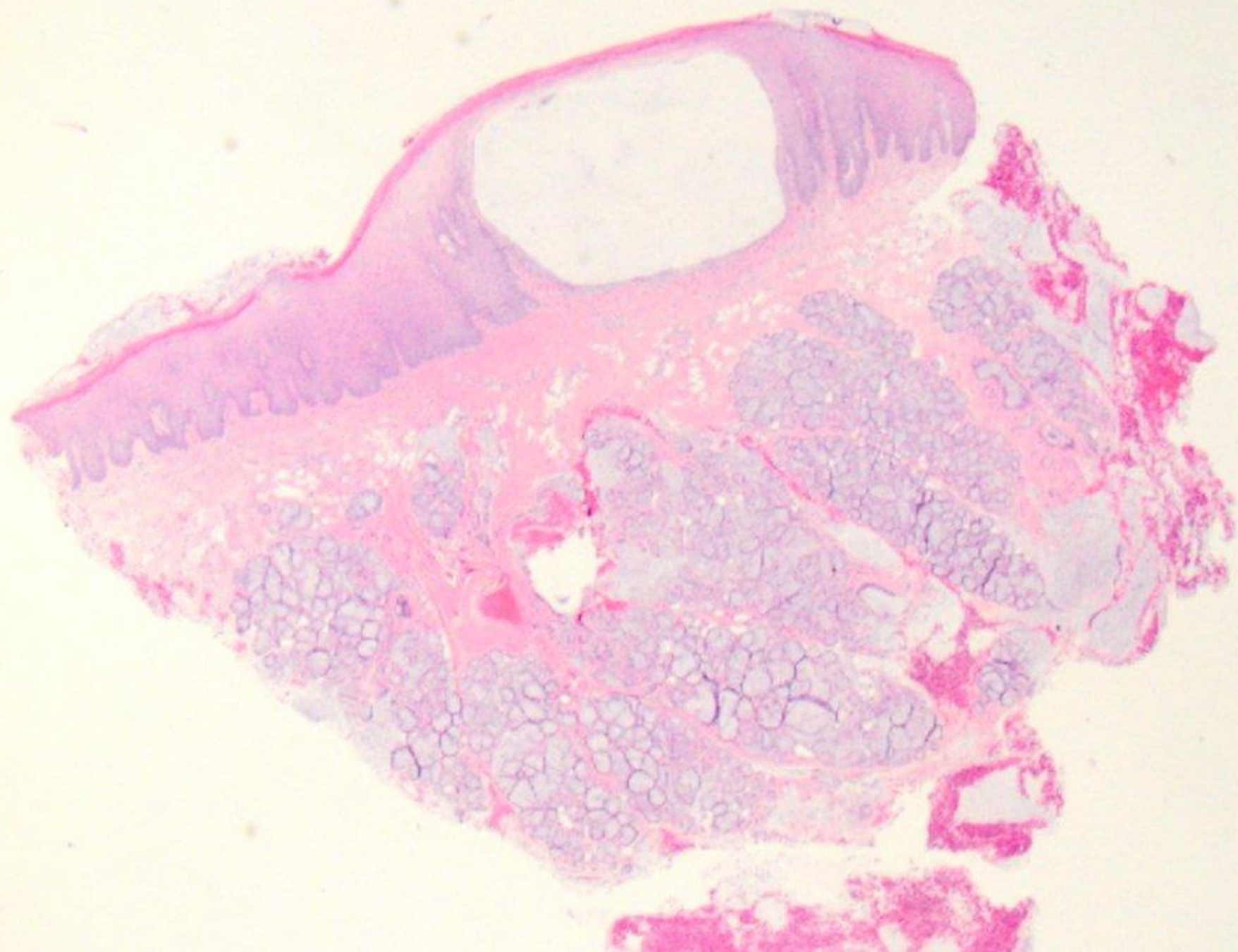


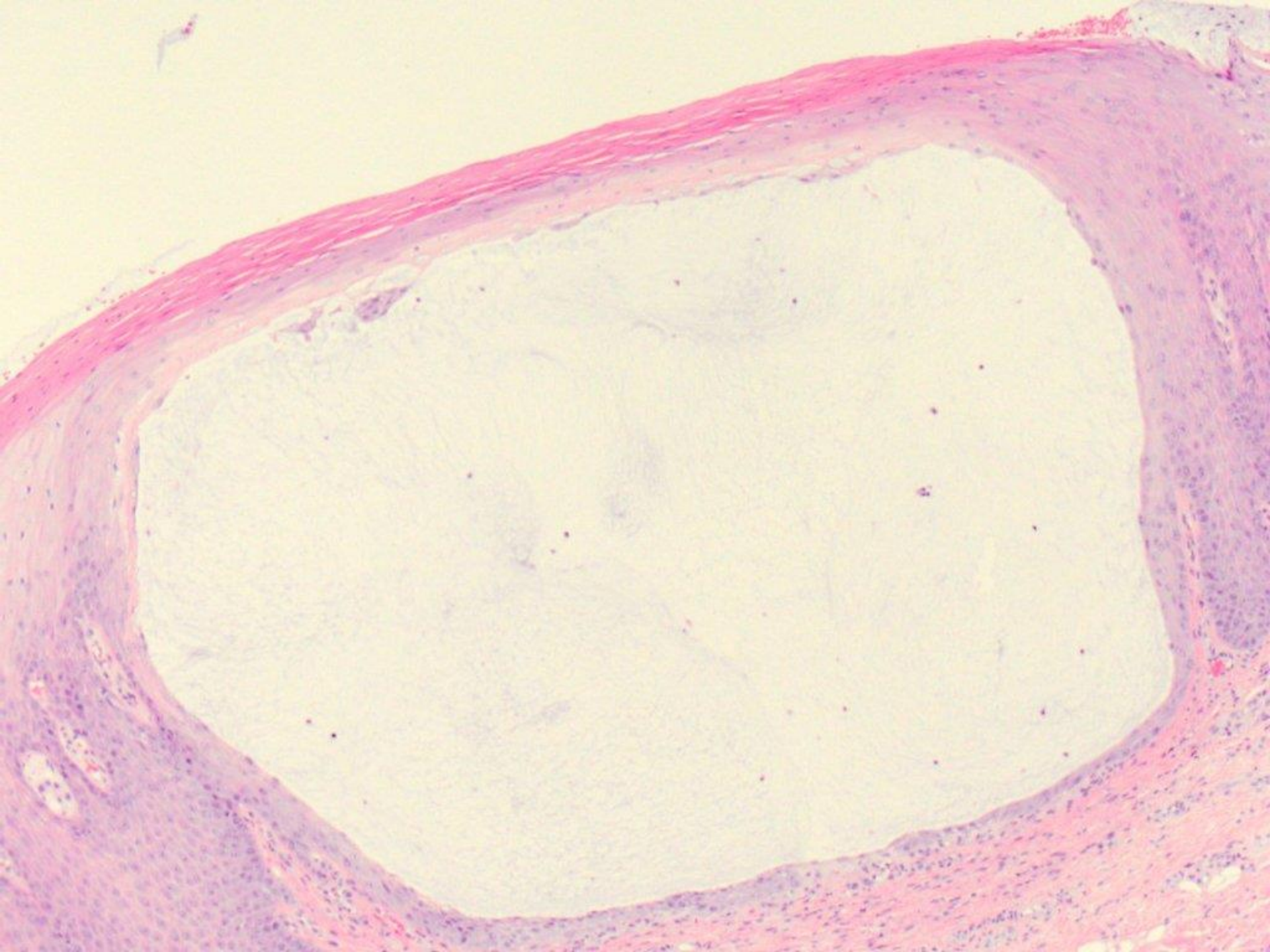
pemphigus

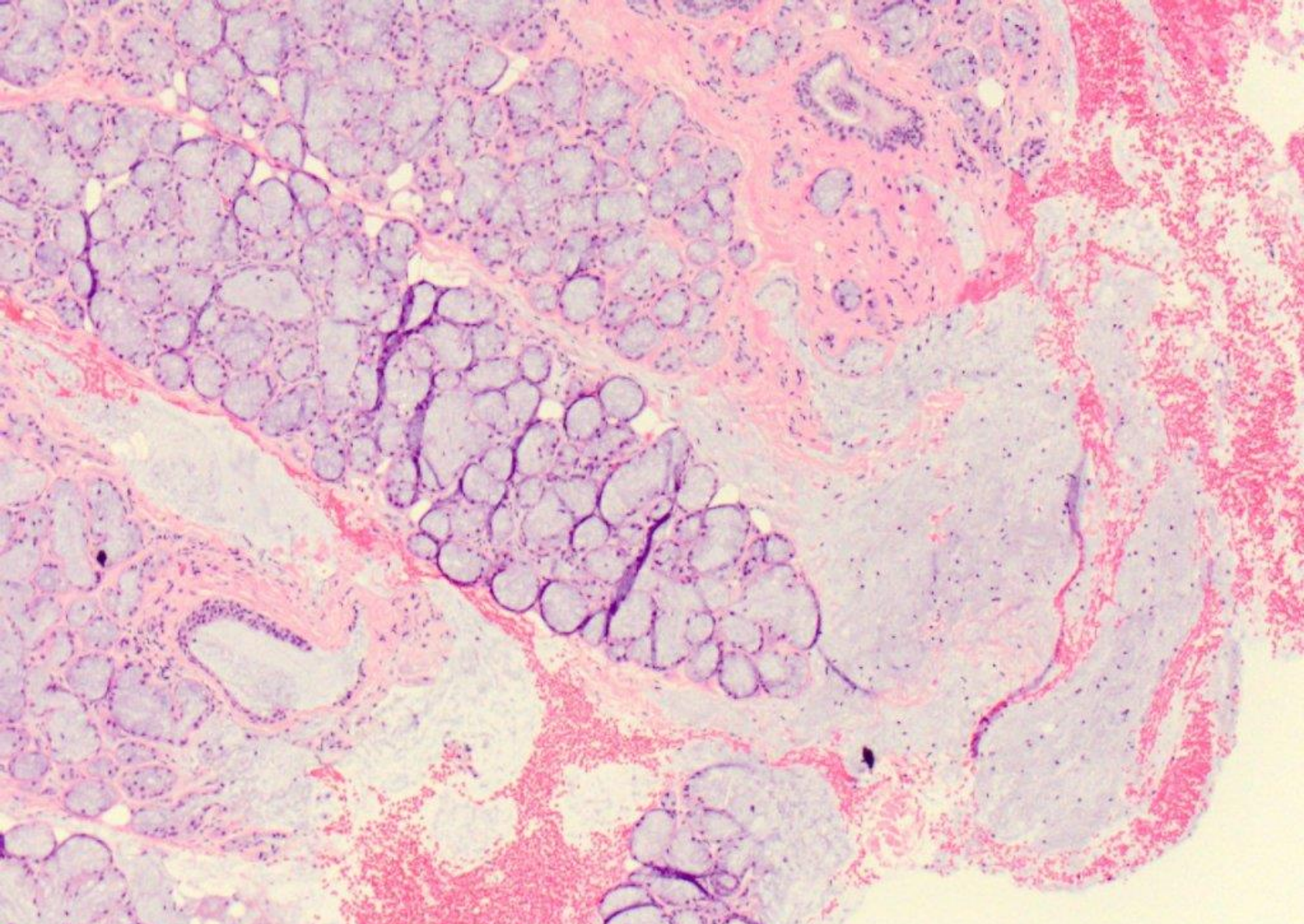




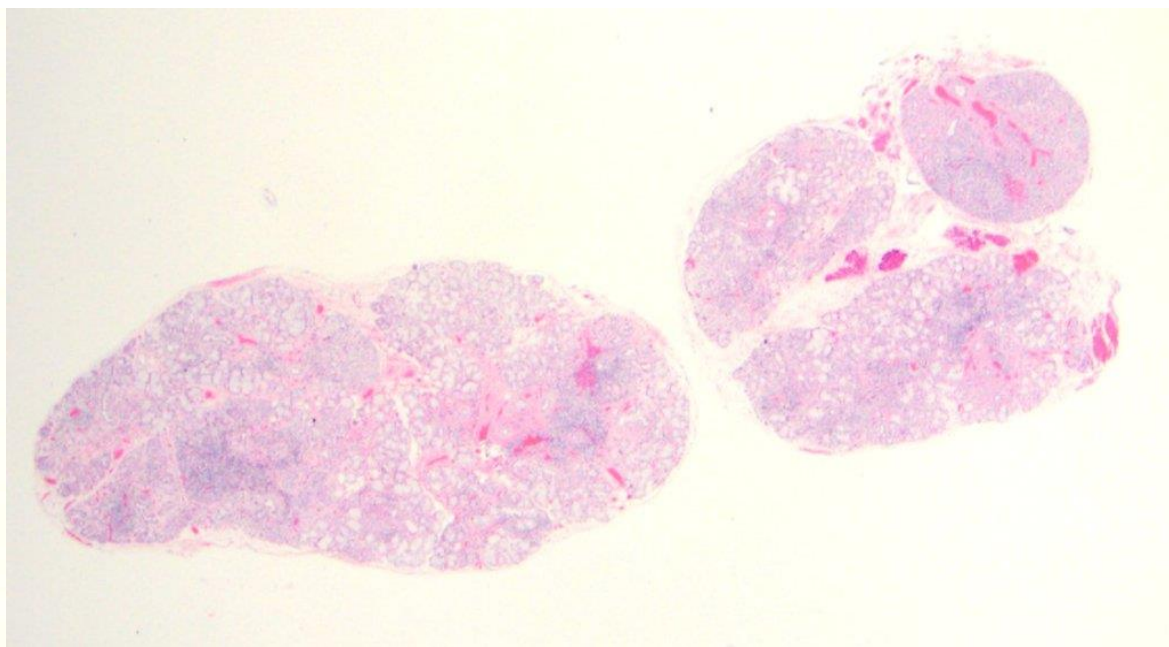
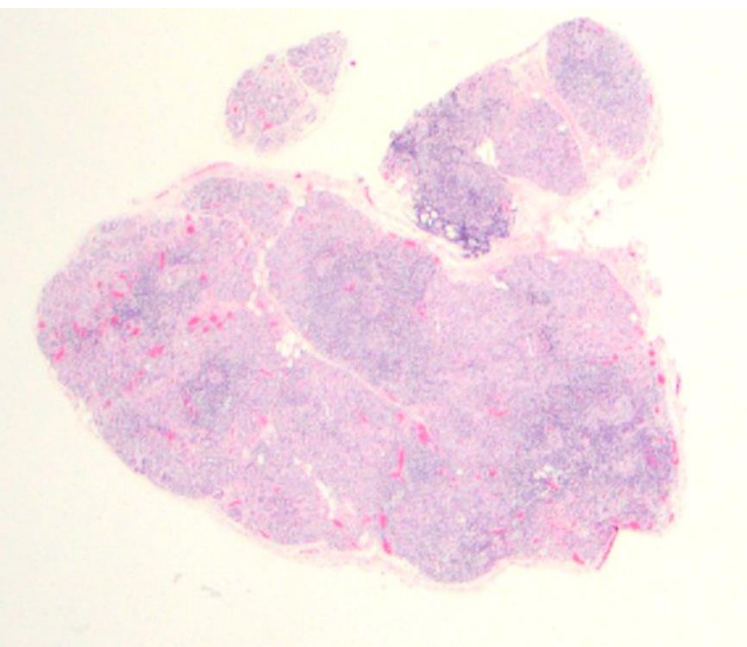
pemphigoid



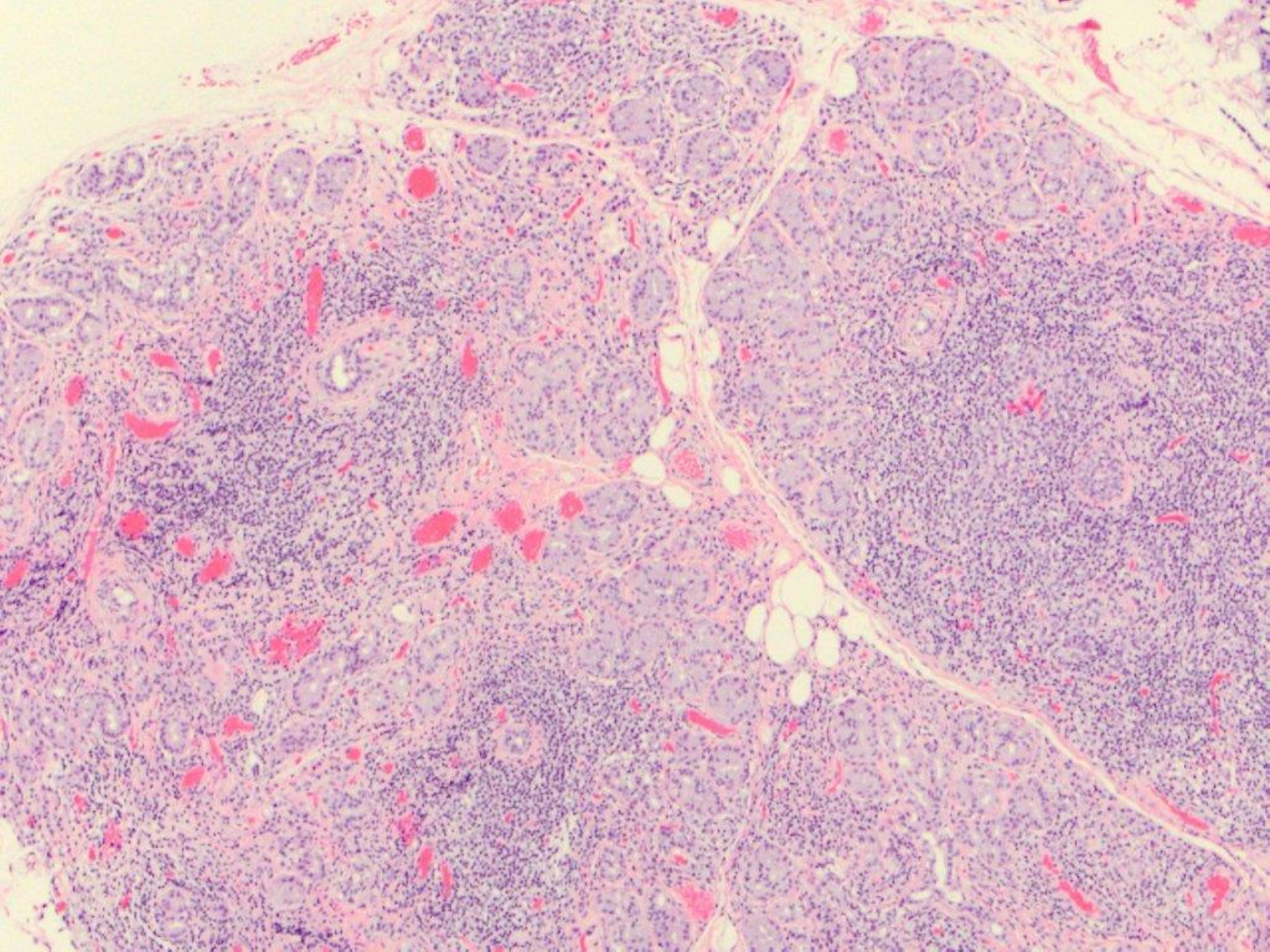


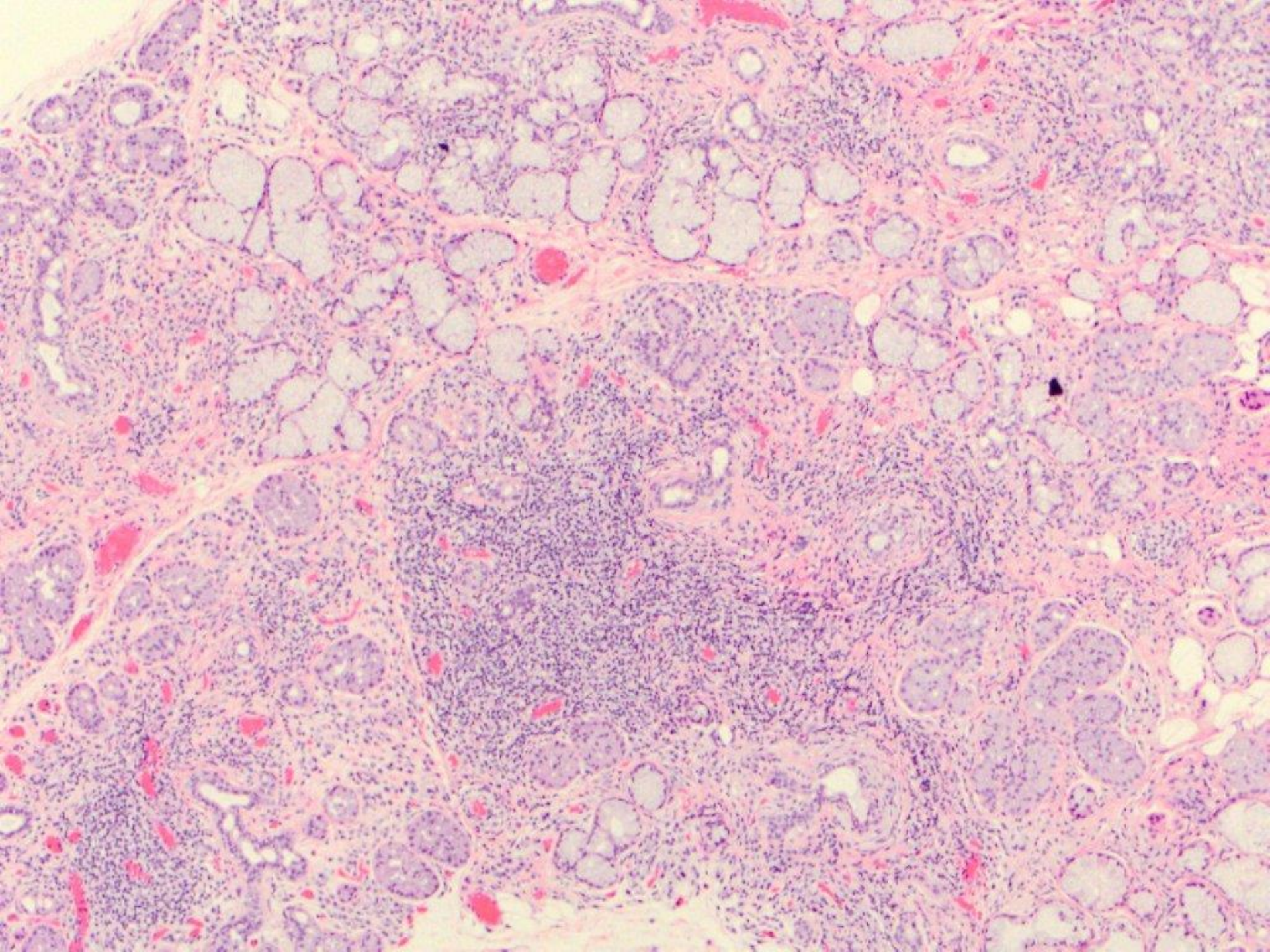


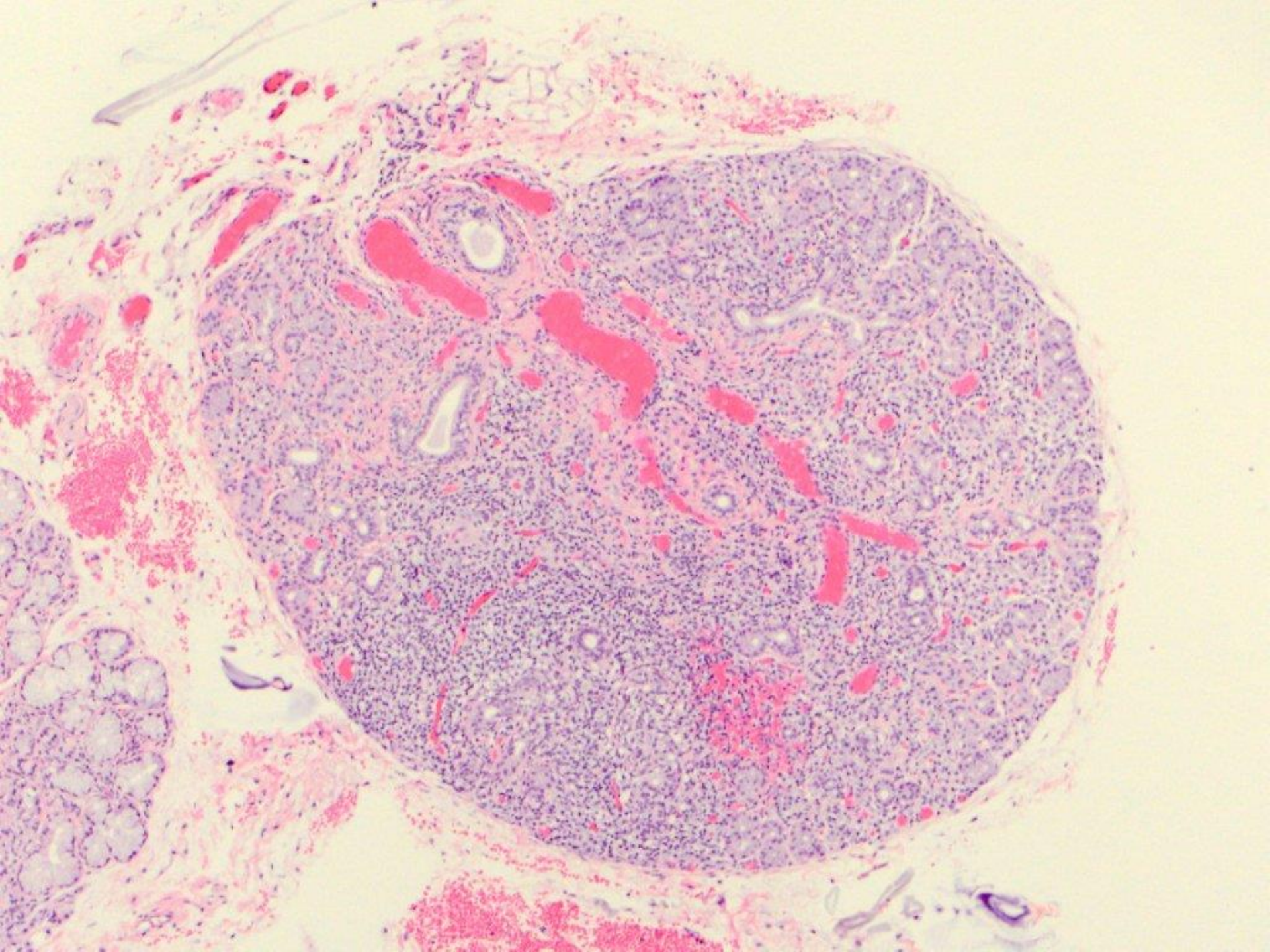
superficial mucocele

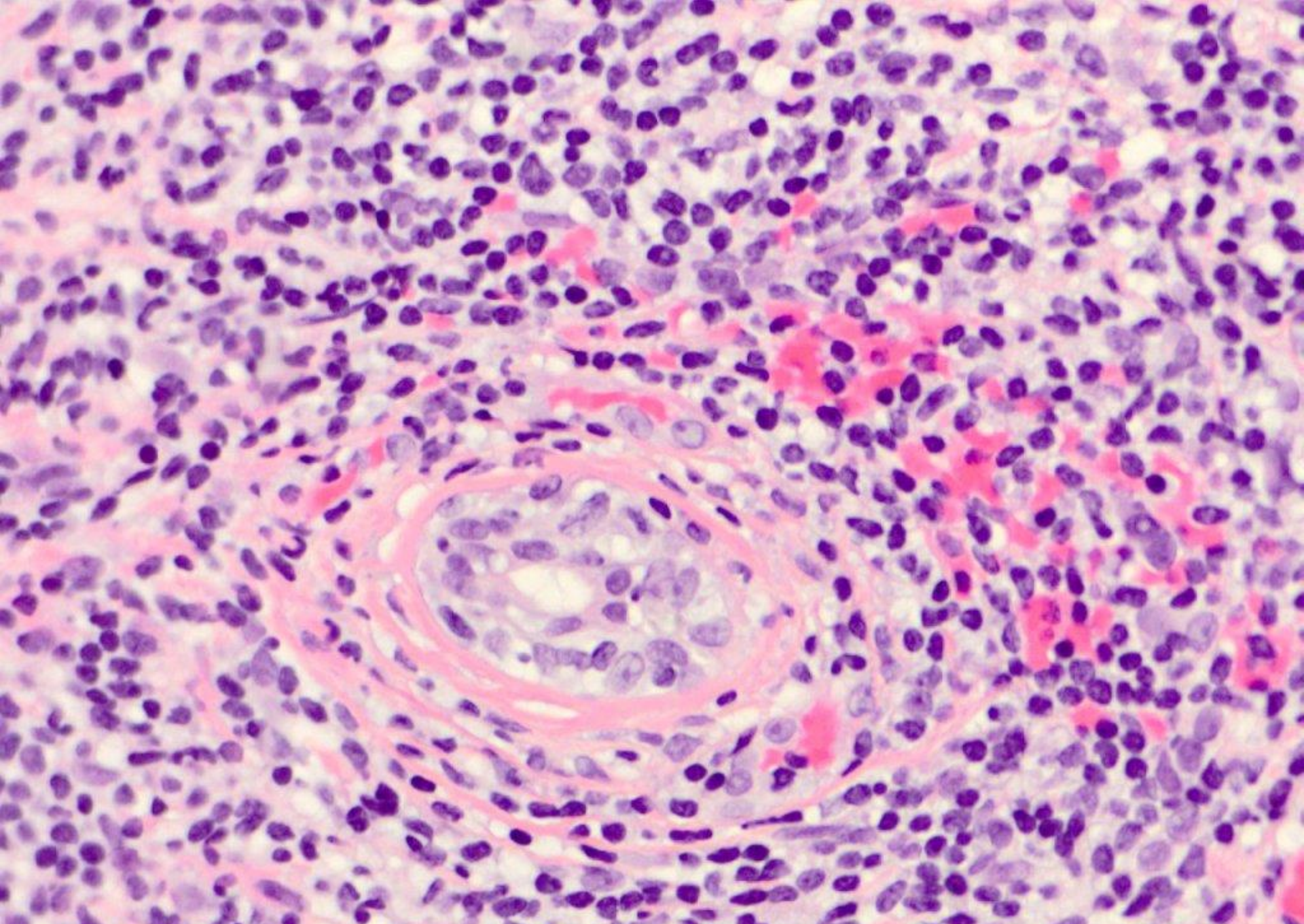


dry mouth, dry eyes, elevated SS-A and SS-B

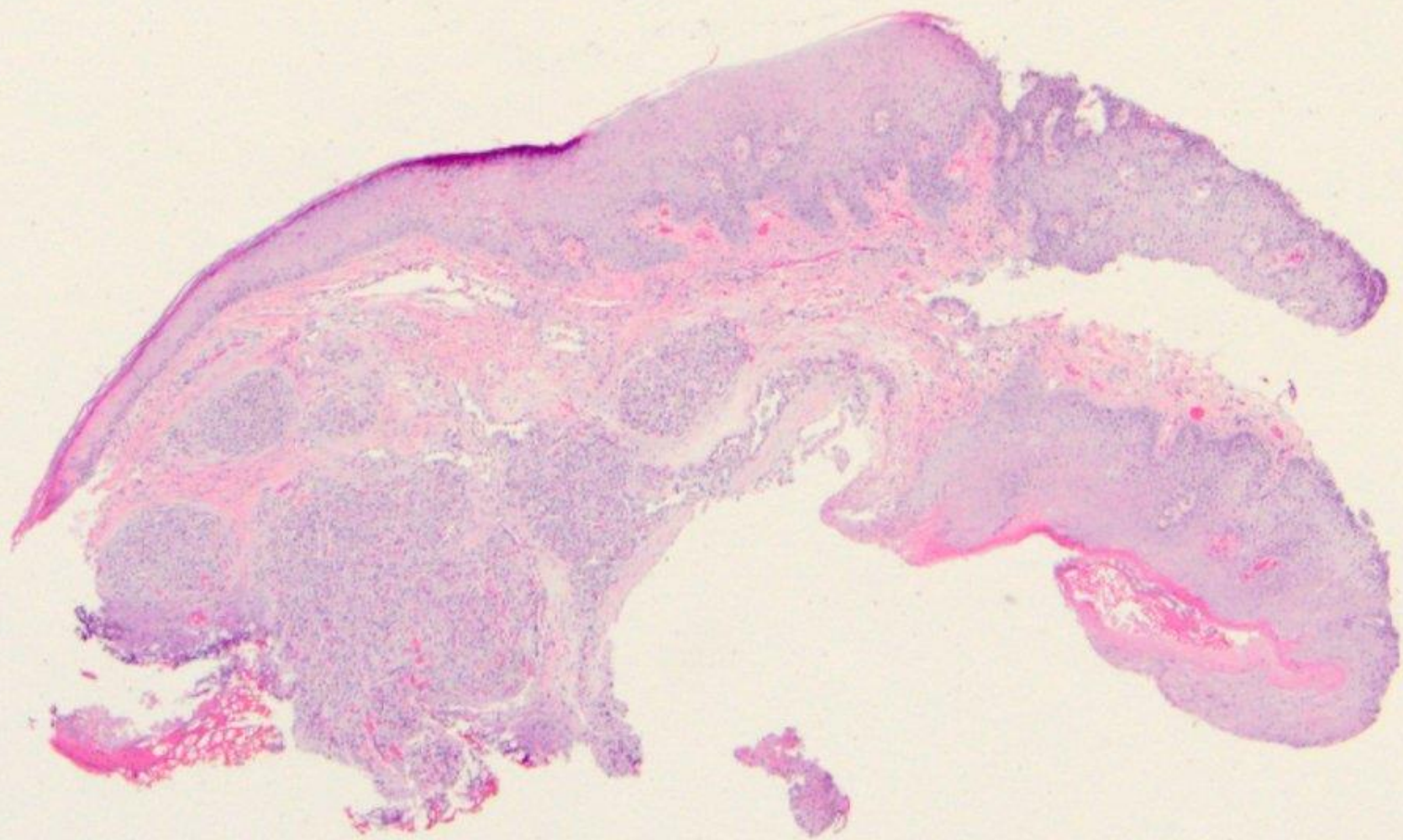


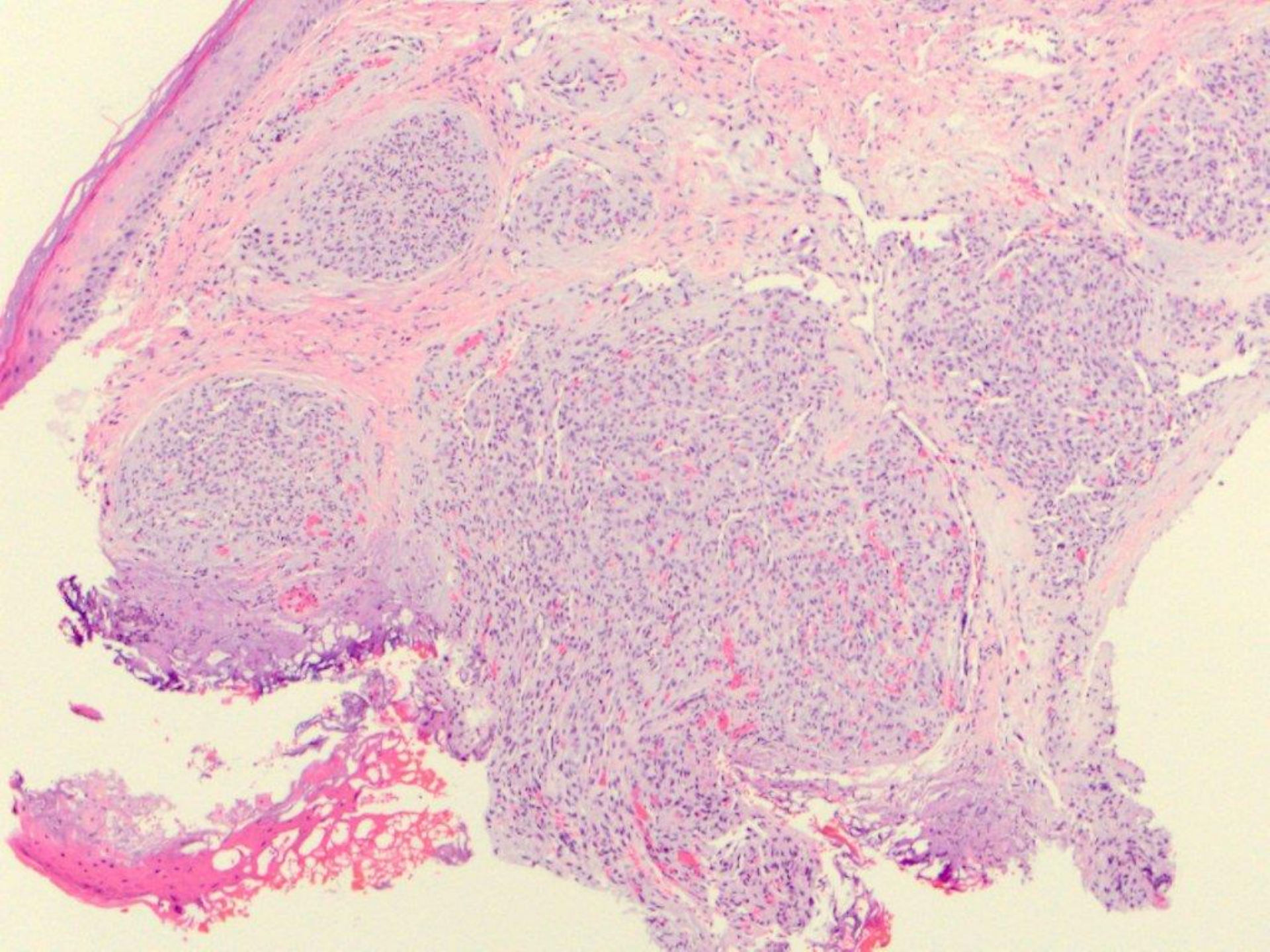


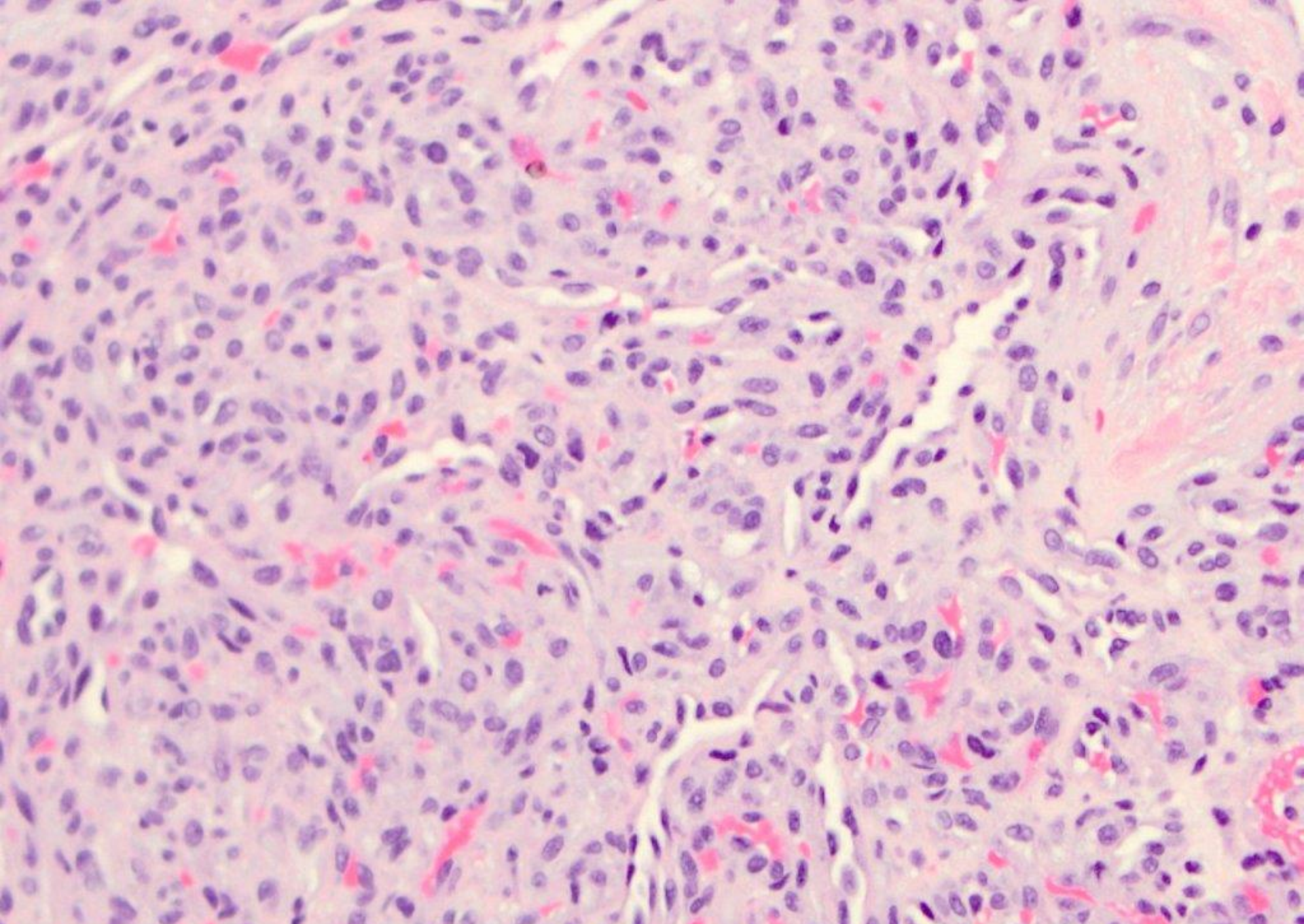




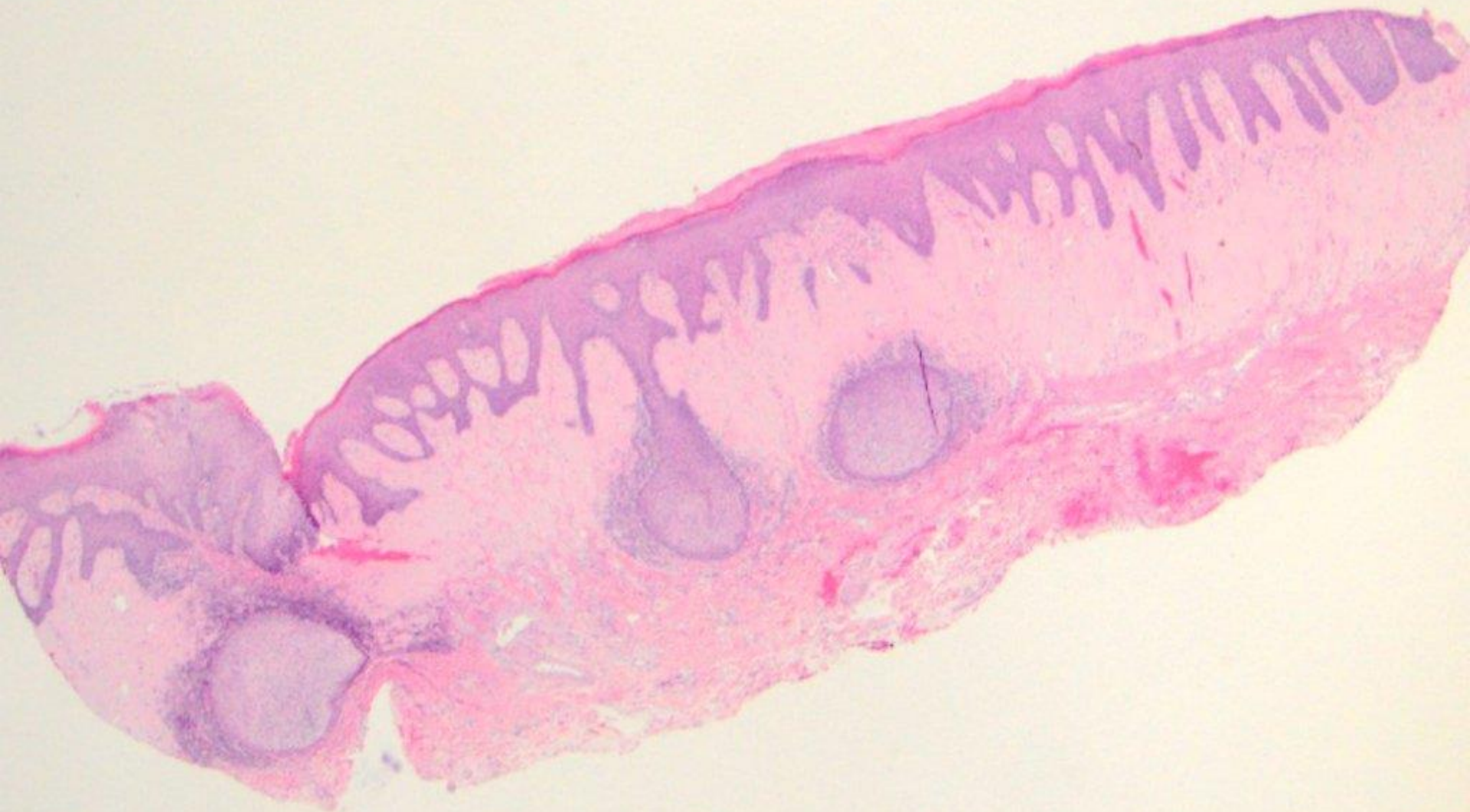
c/w Sjogren's Syndrome



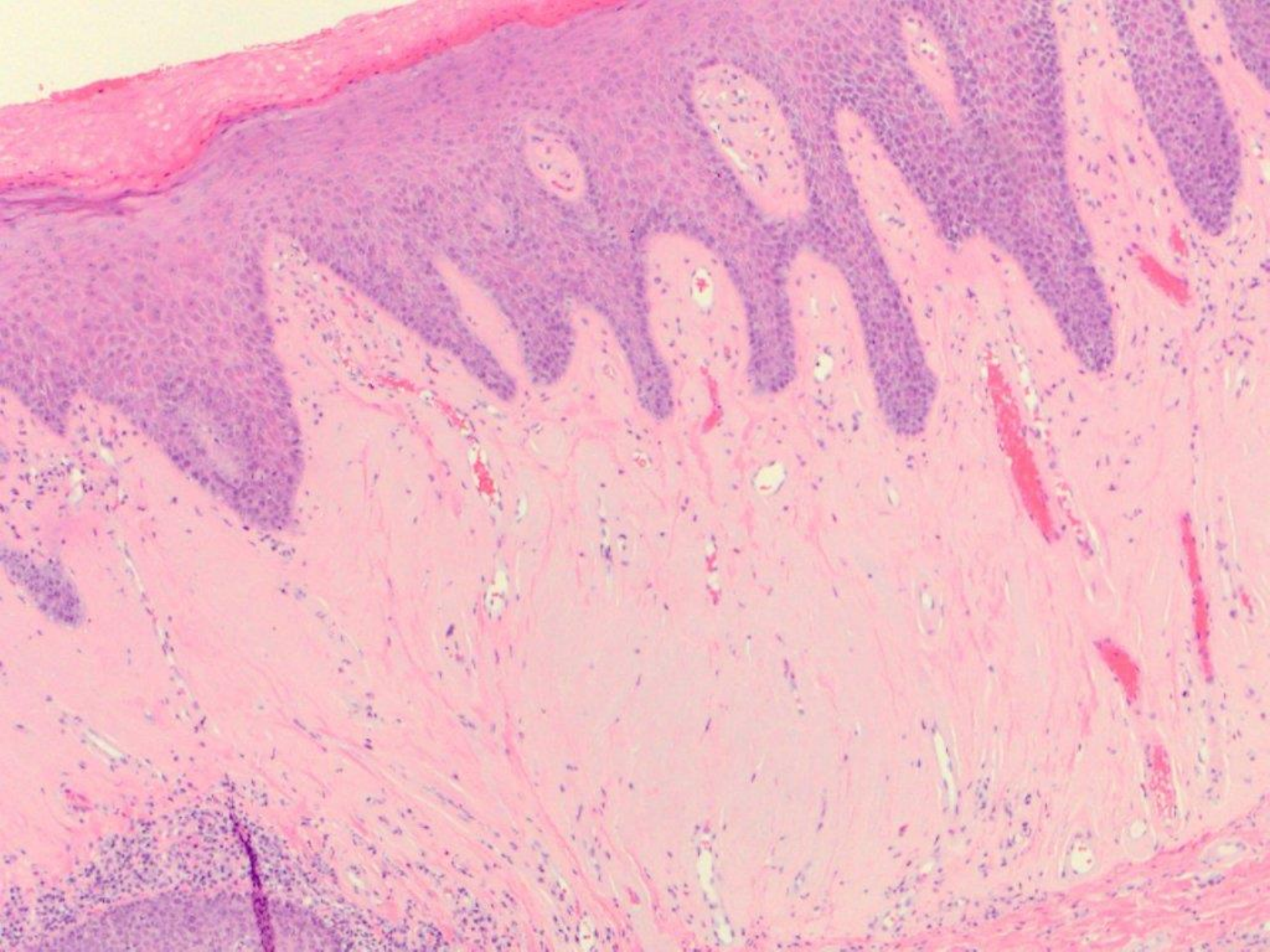


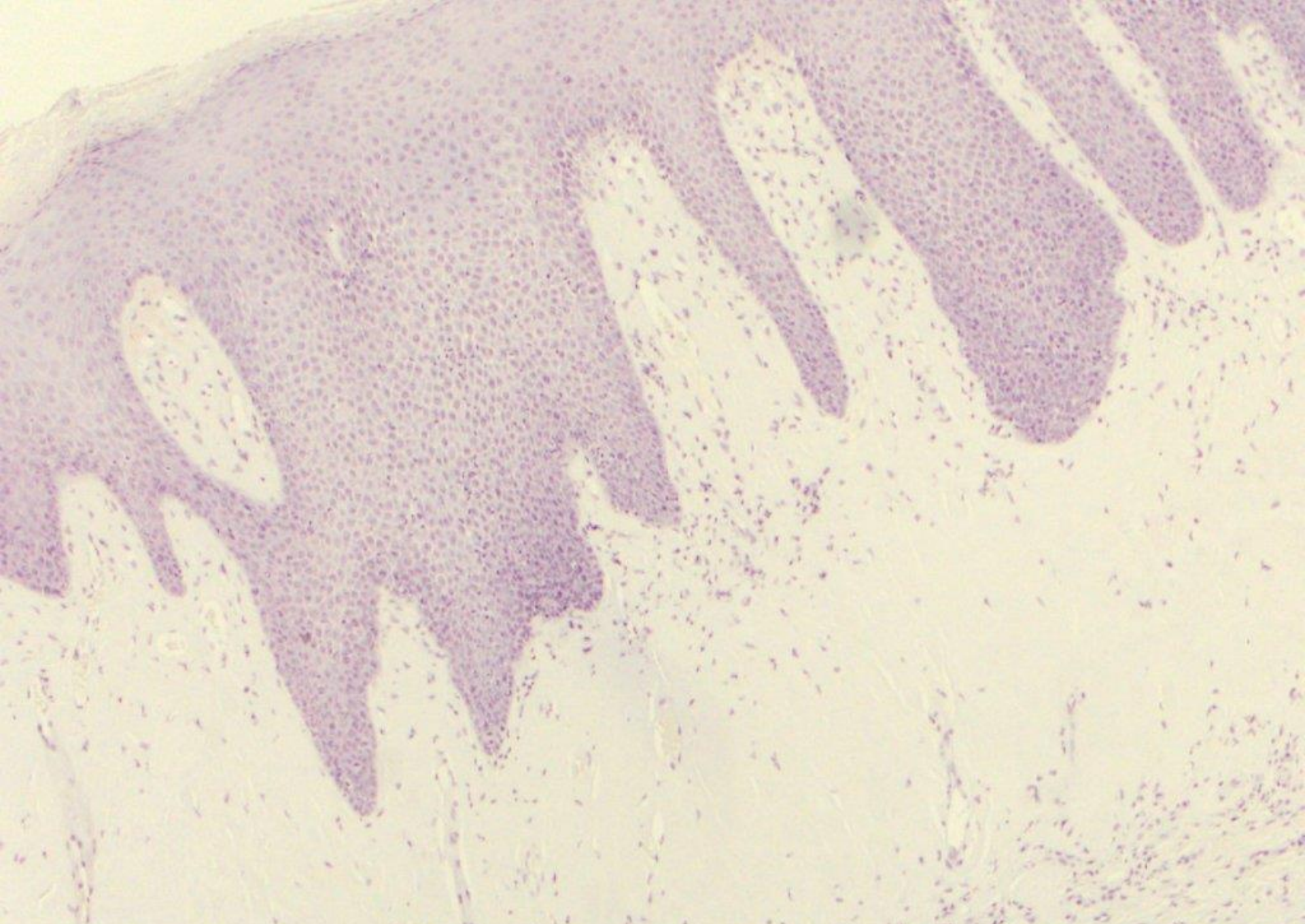


lobular capillary hemangioma



smokeless tobacco user

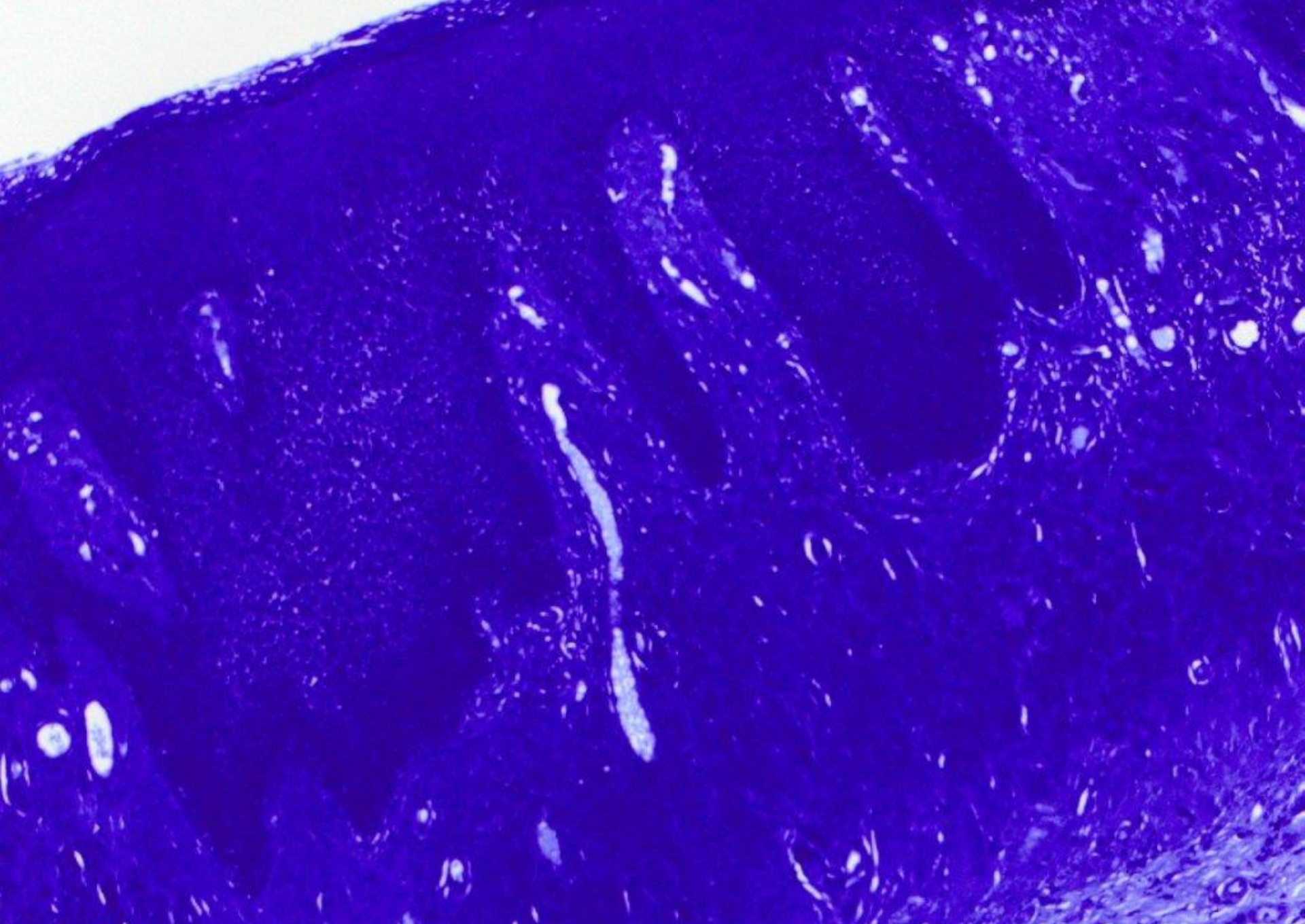




Congo Red, unpolarized

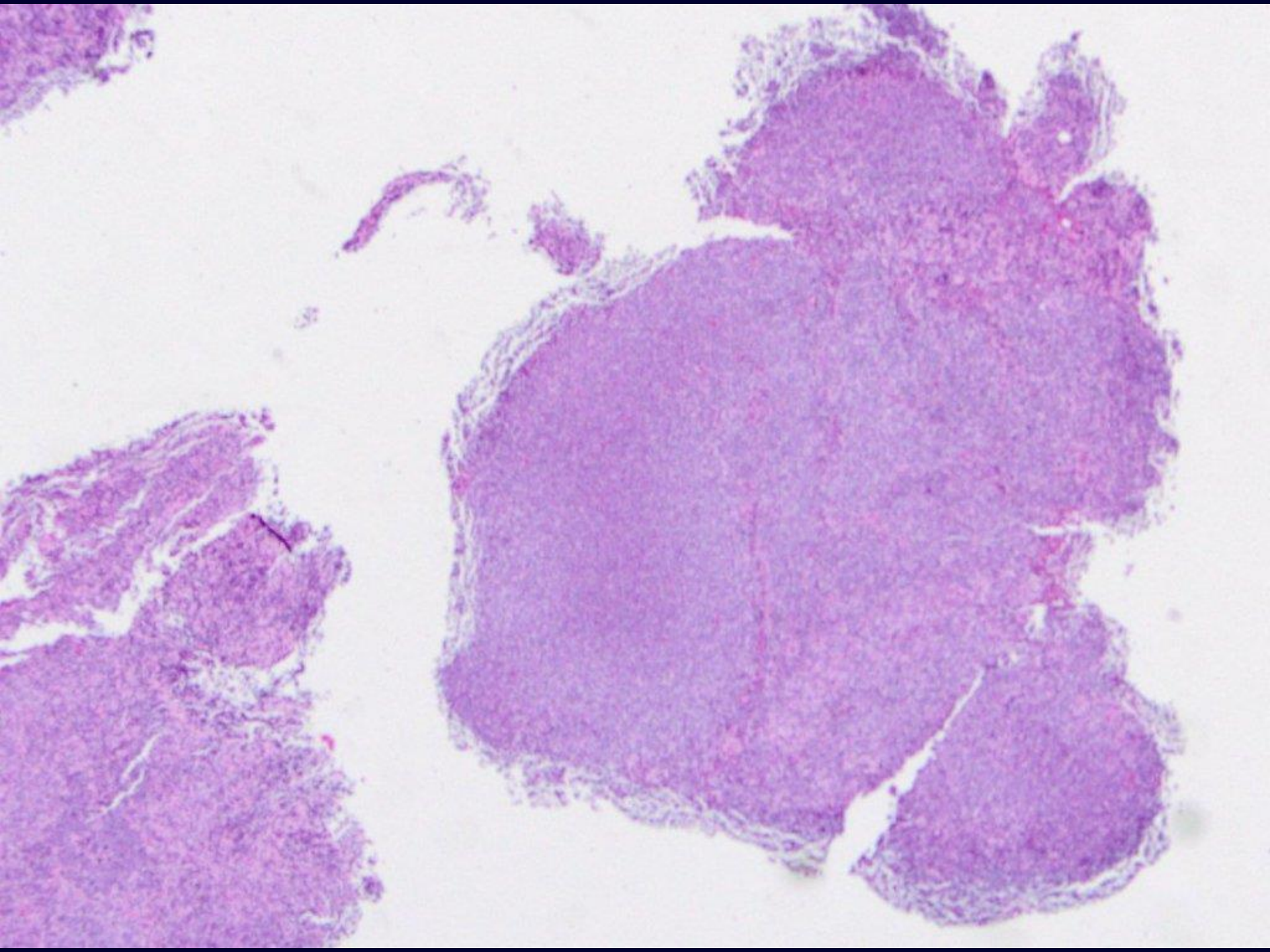


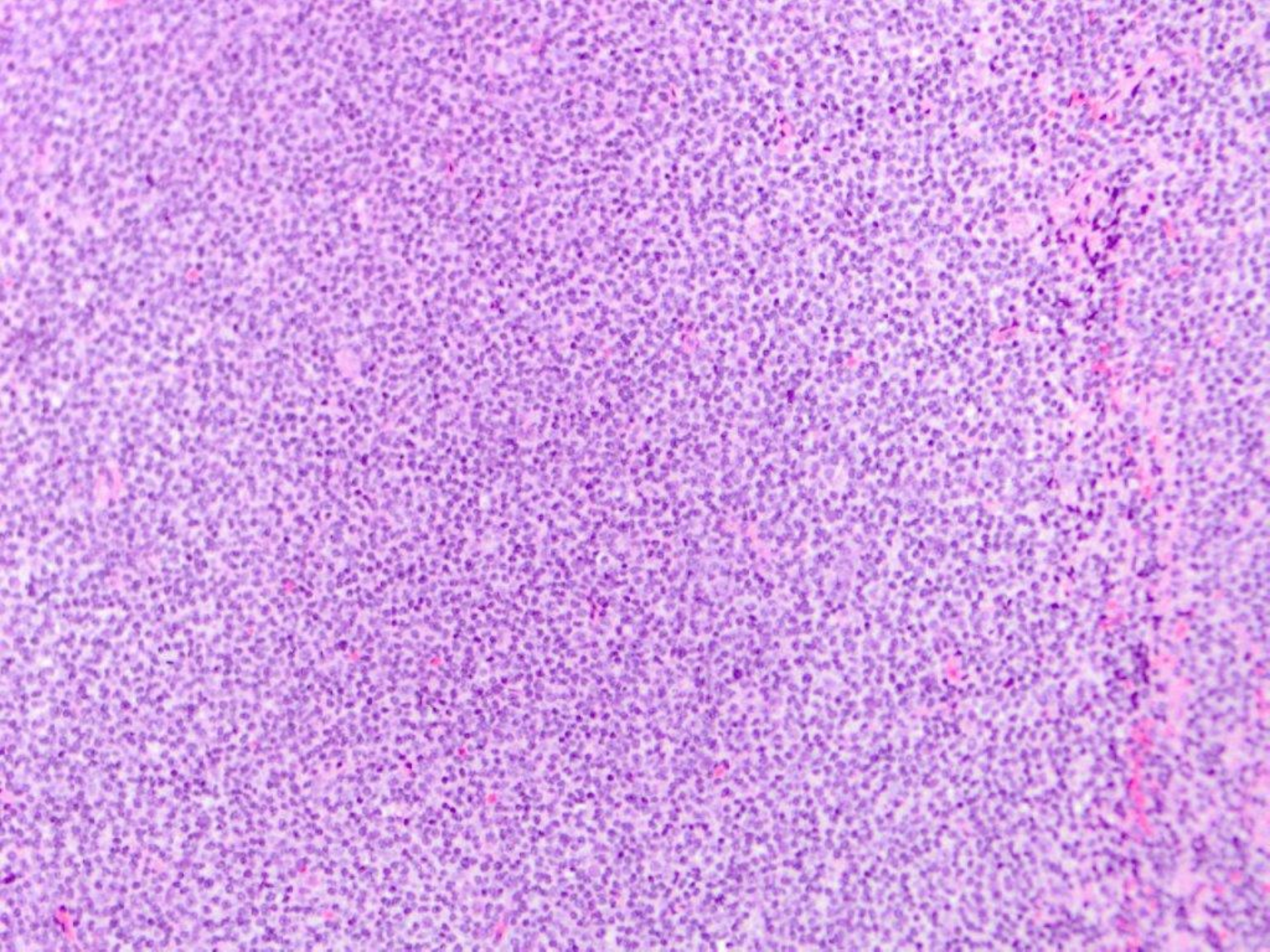
Congo Red, polarized

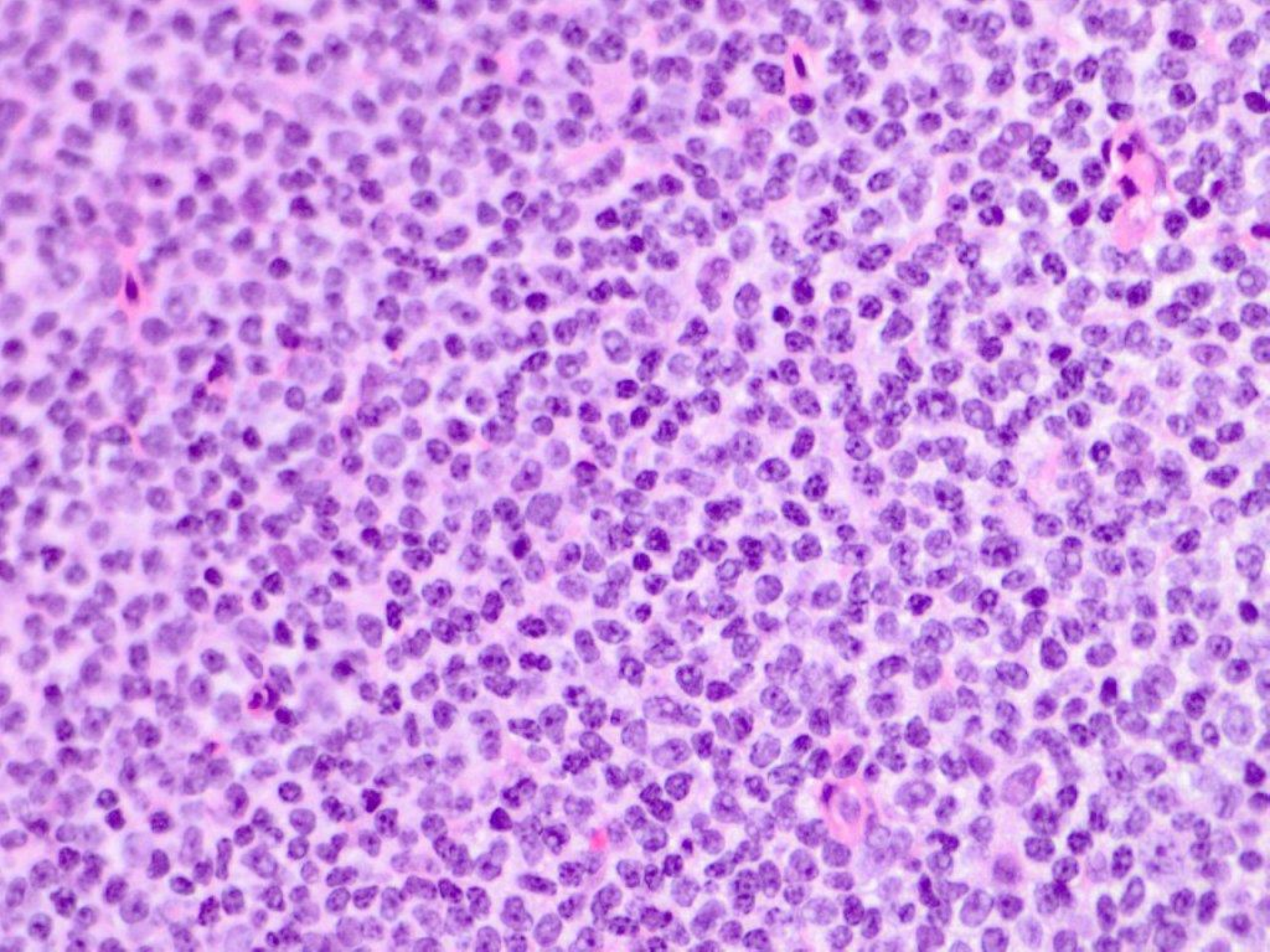


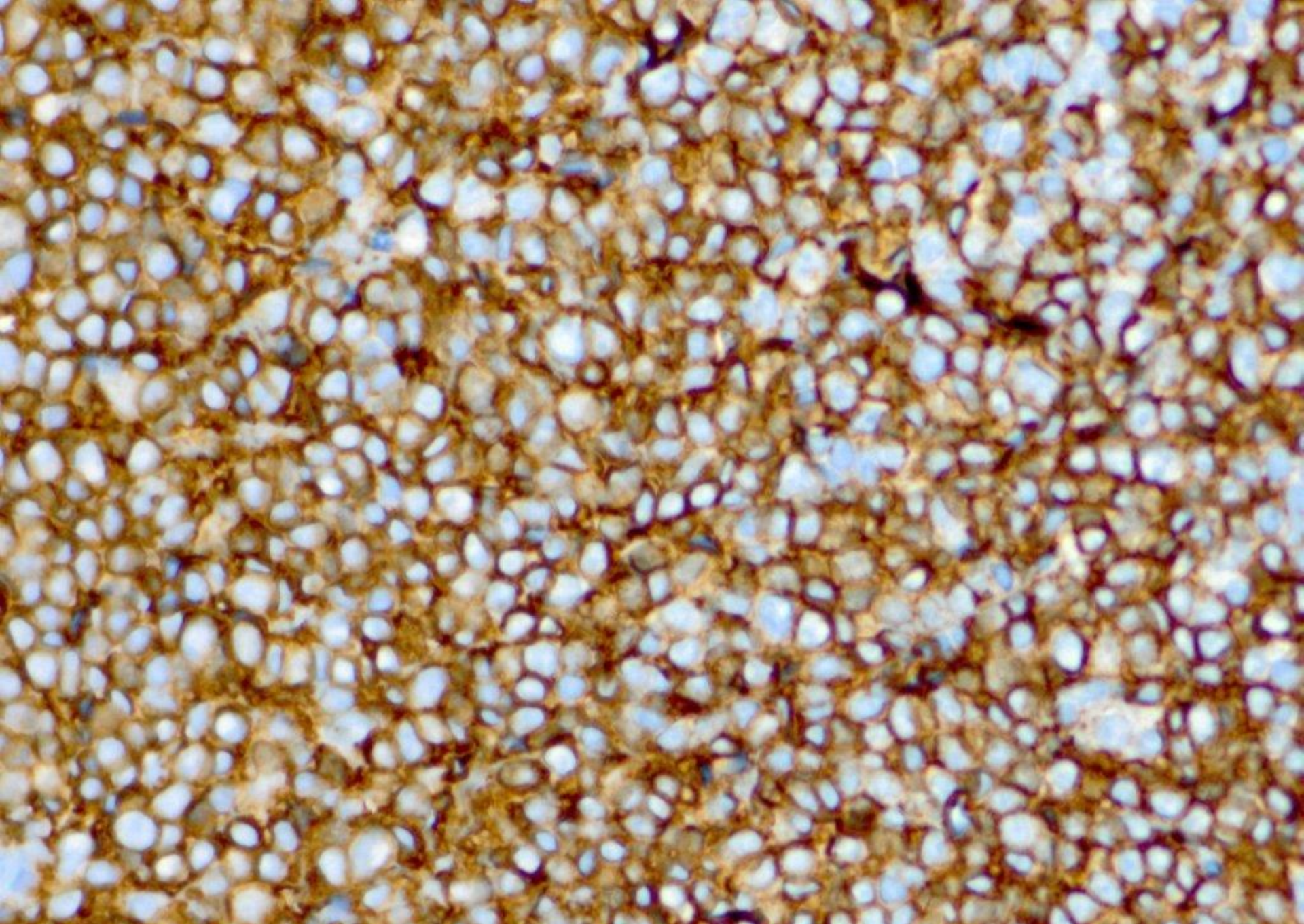
Crystal violet

smokeless tobacco keratosis (not amyloid)

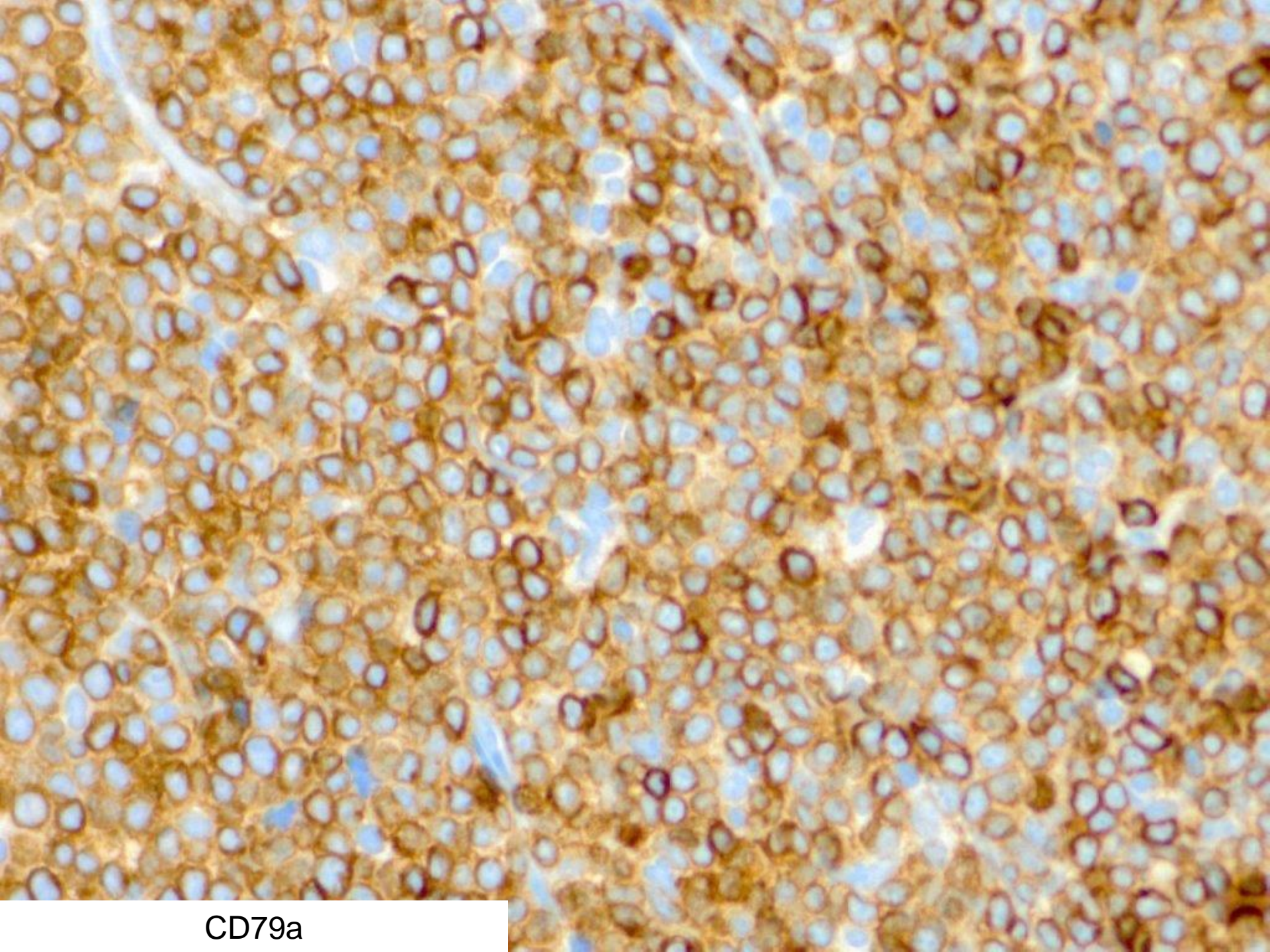




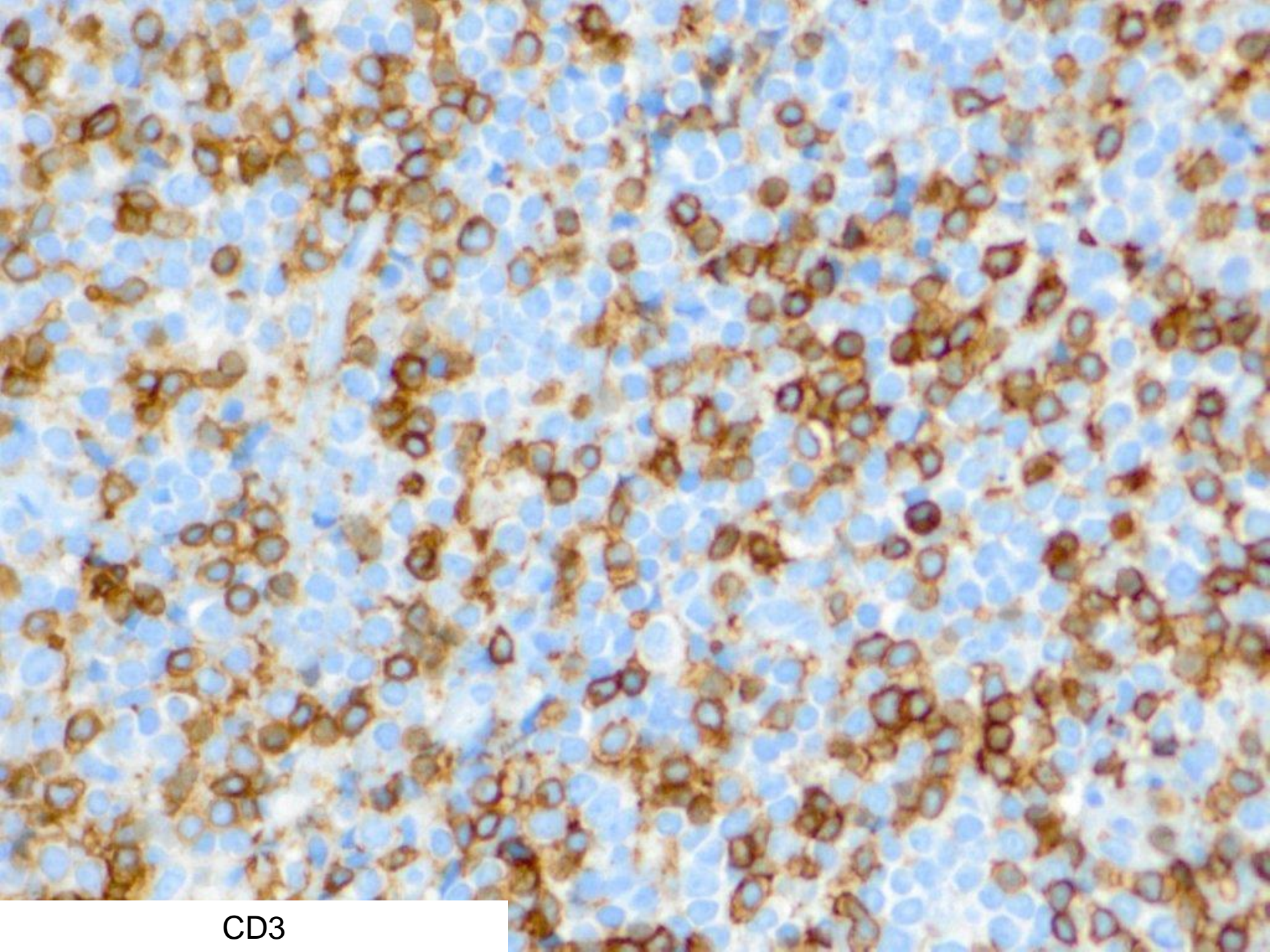




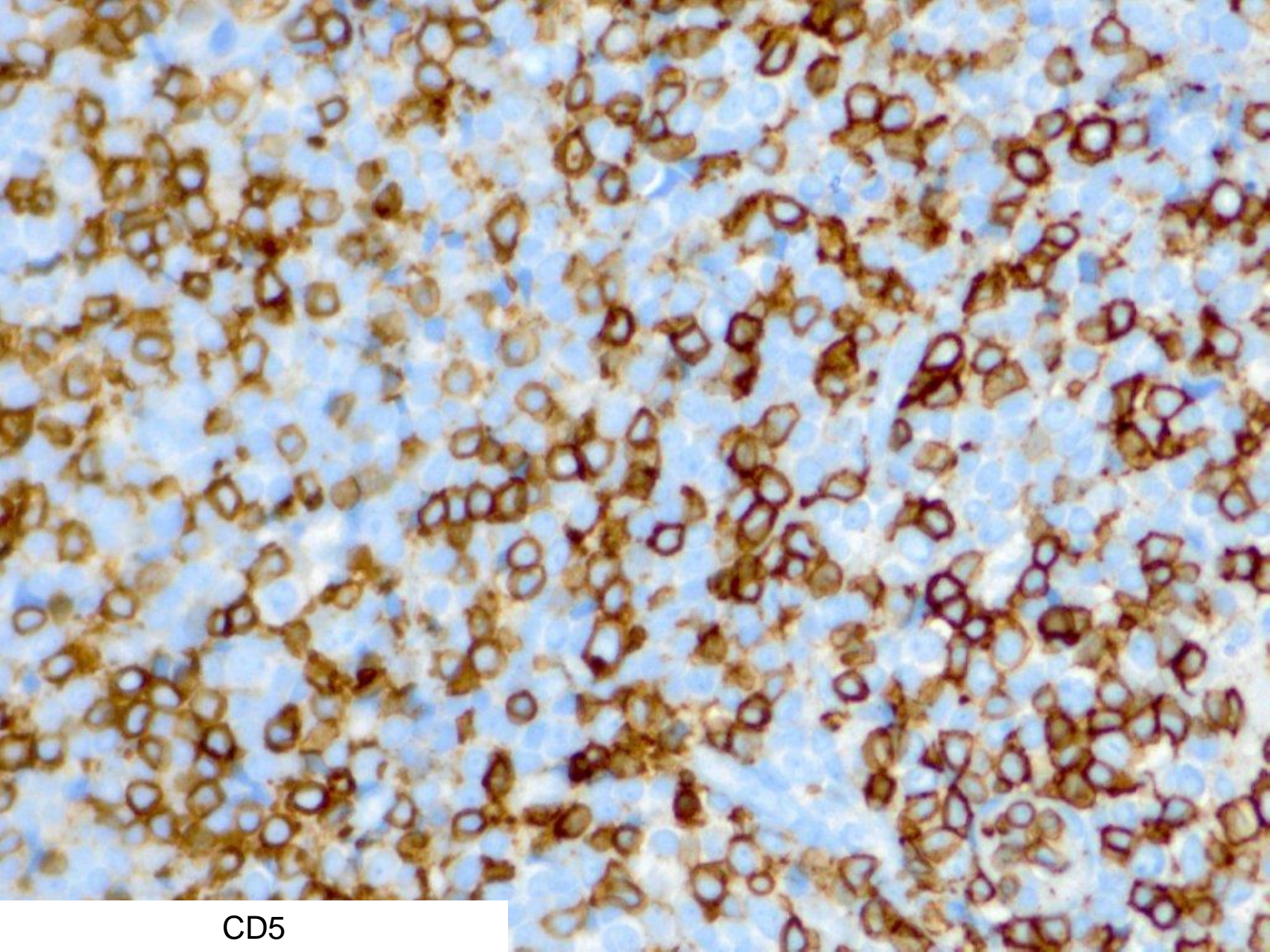
CD20



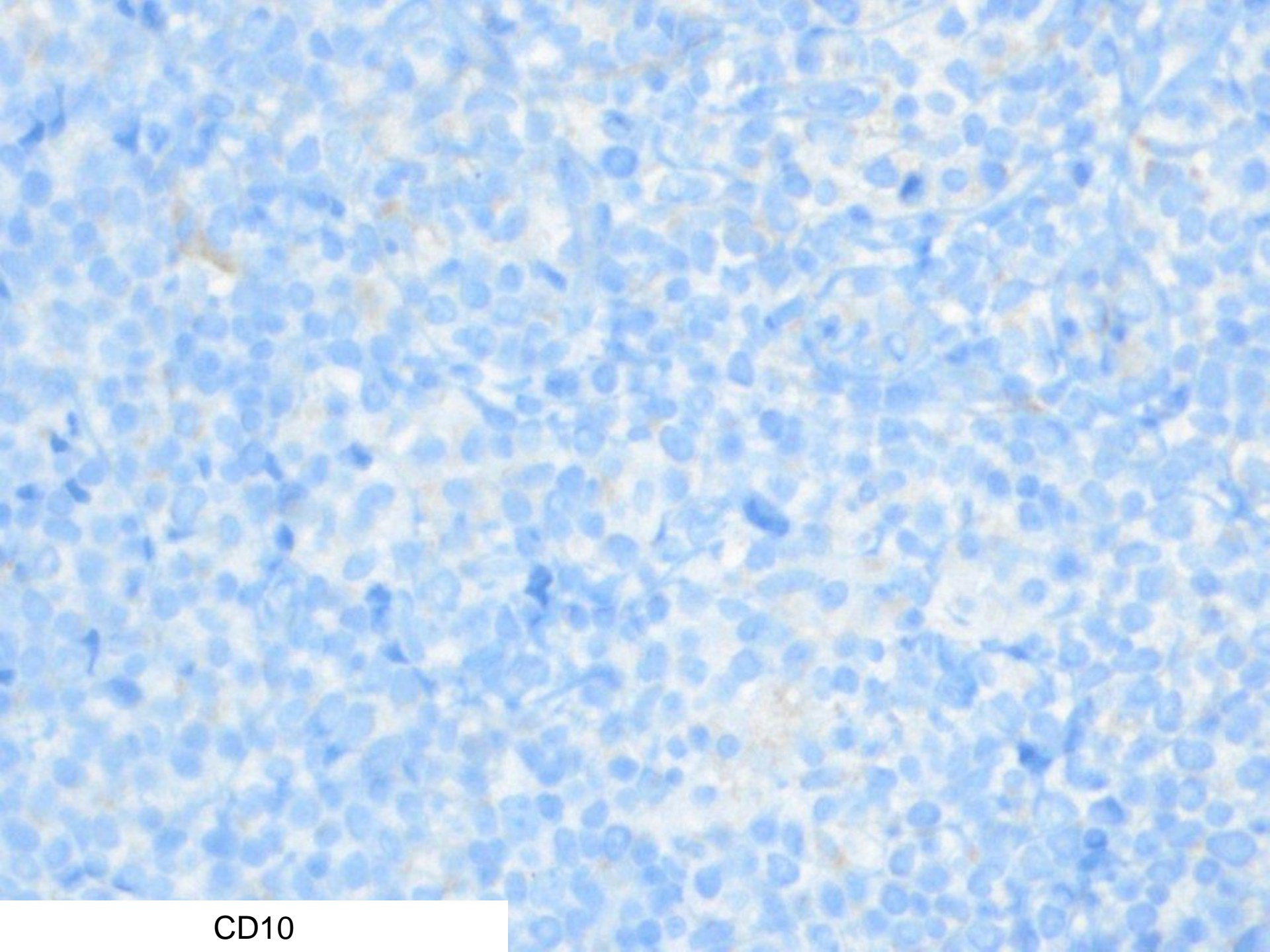
CD79a



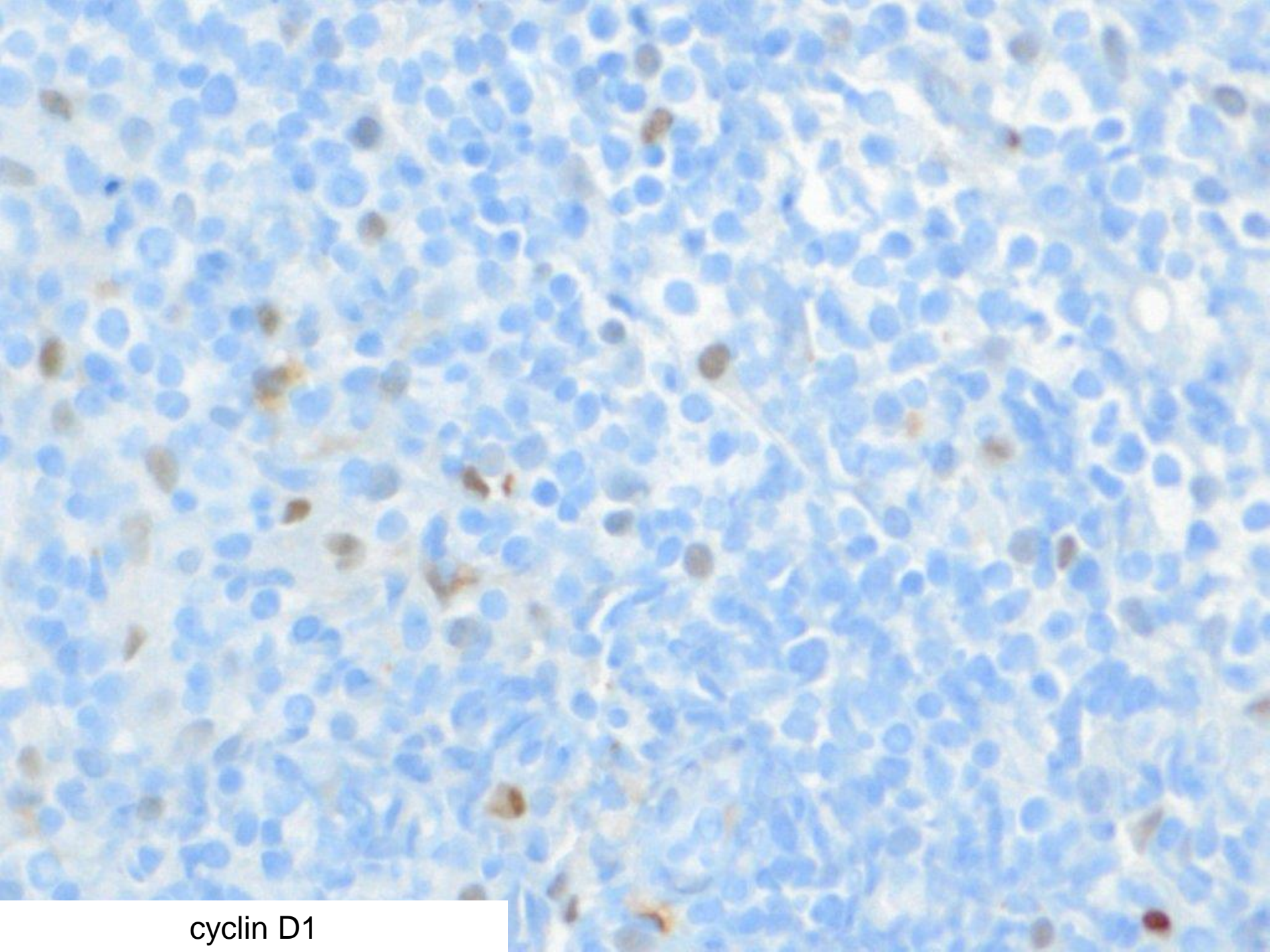
CD3



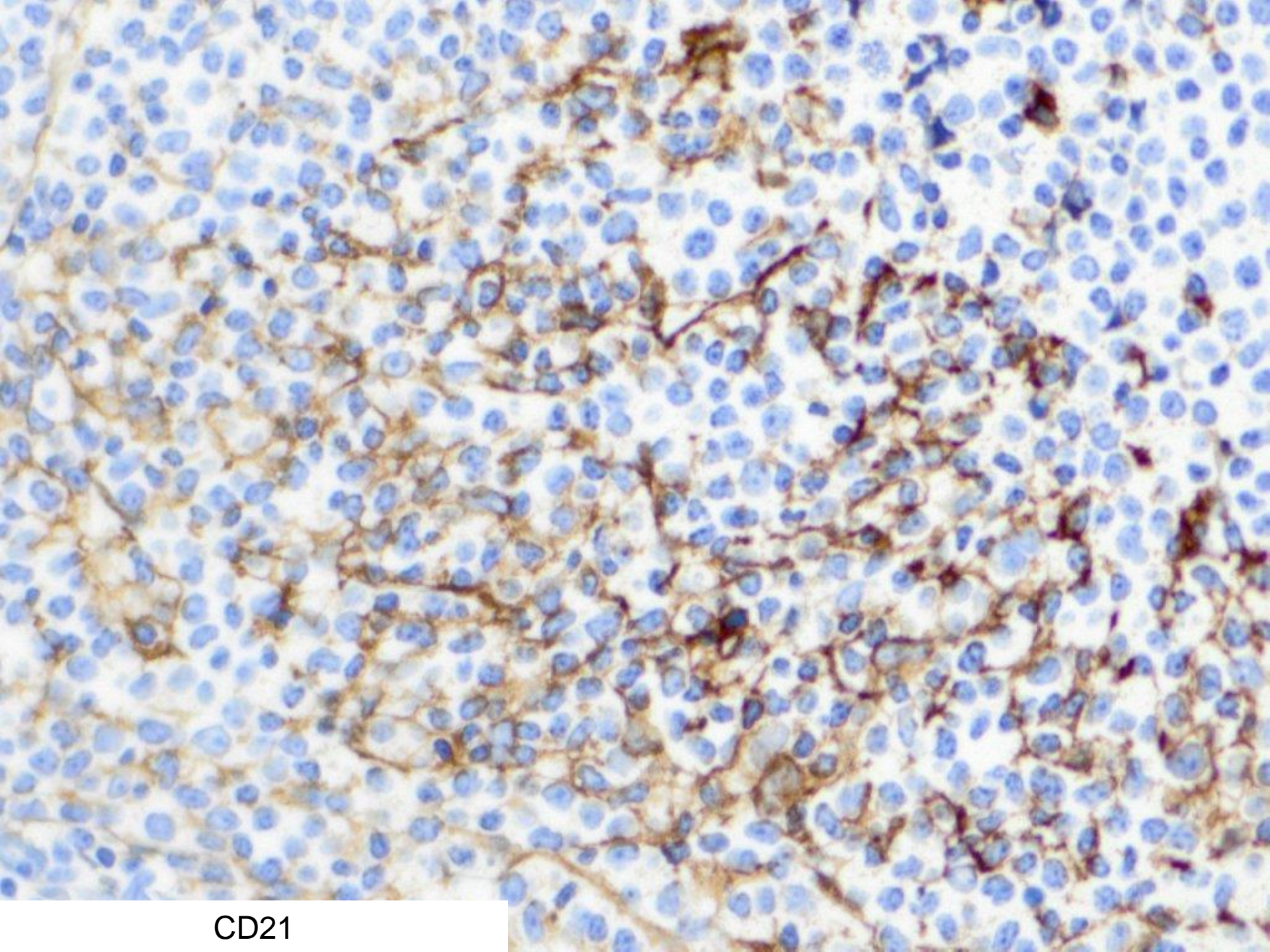
CD5



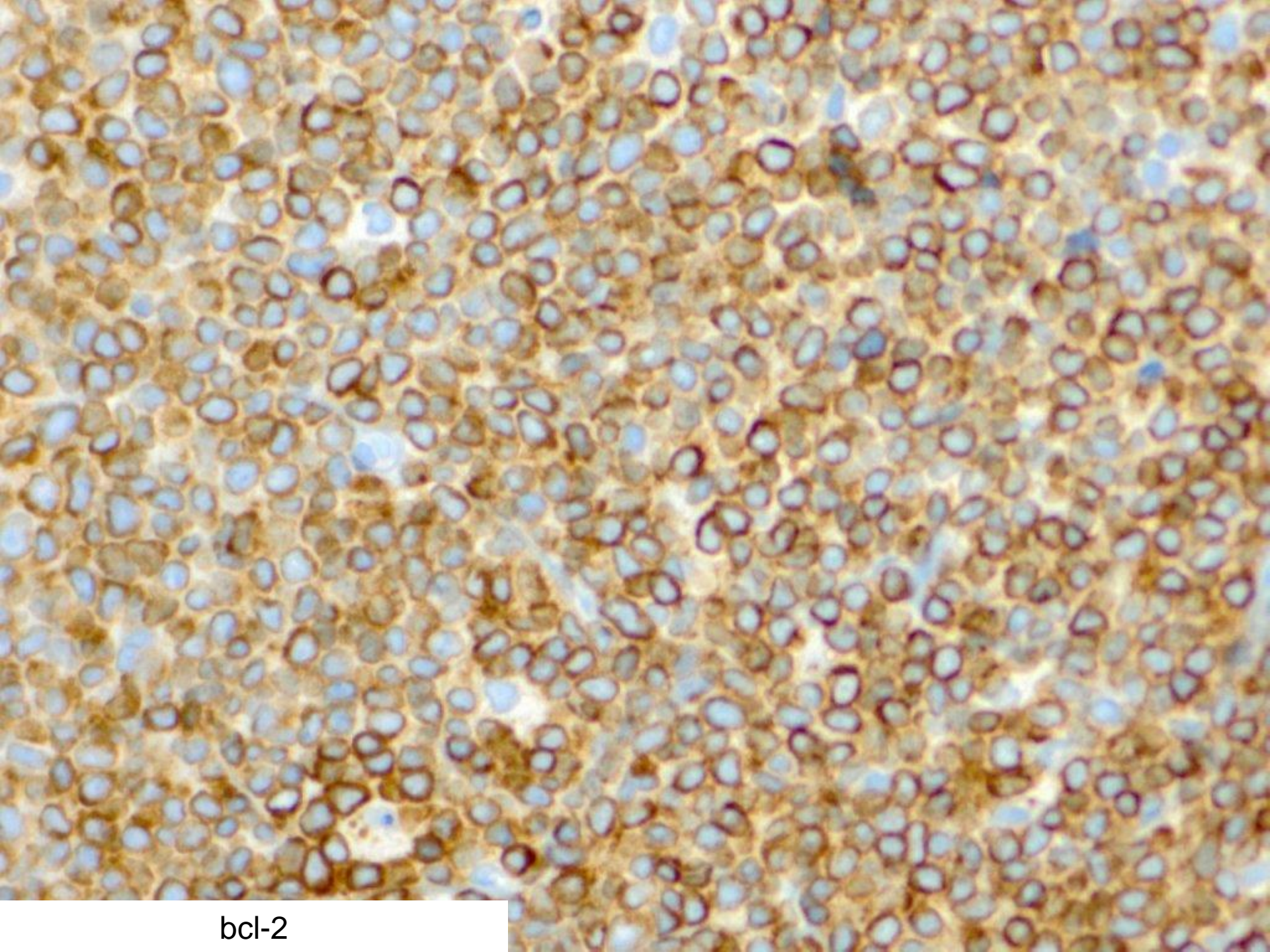
CD10



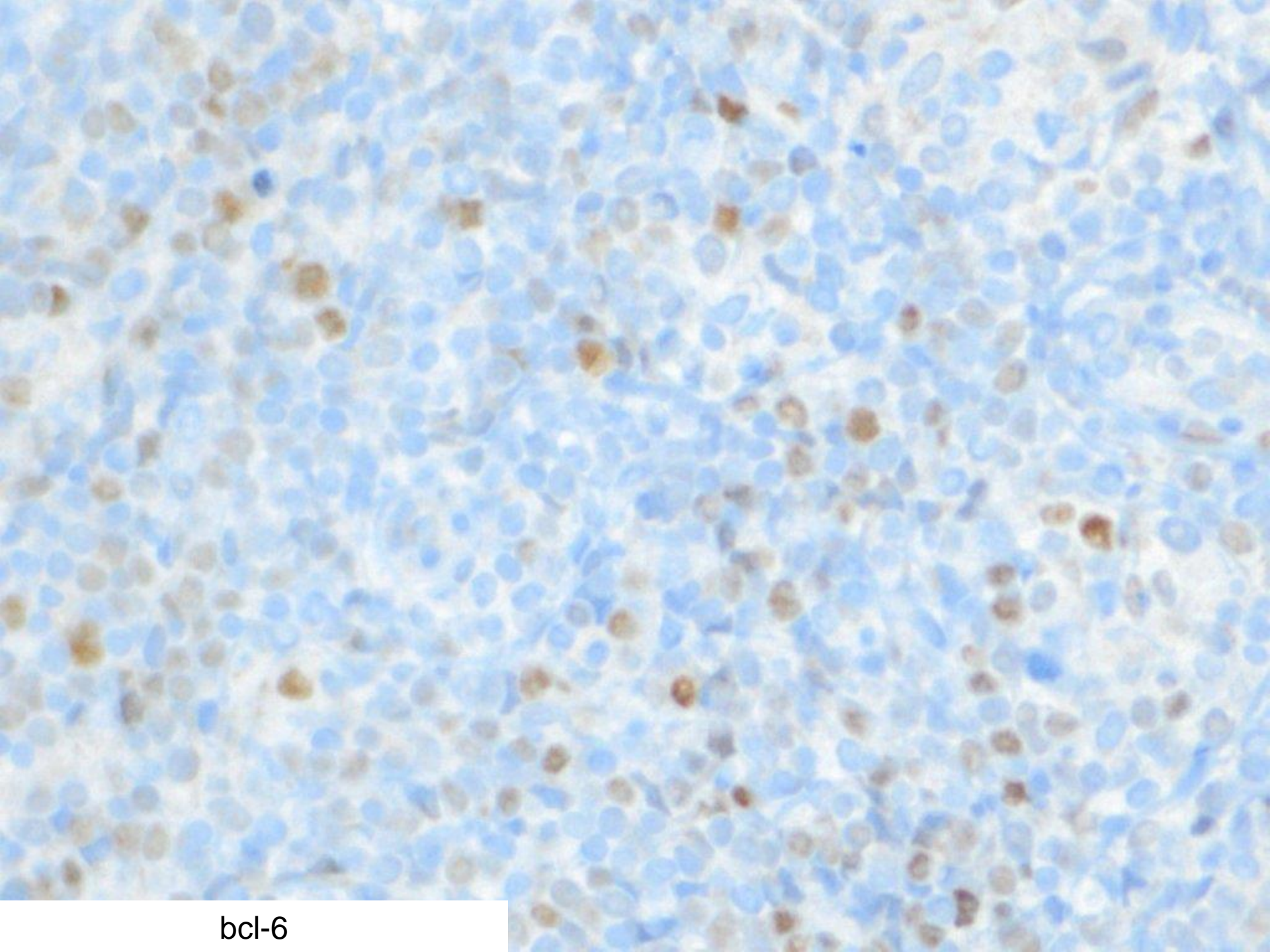
cyclin D1



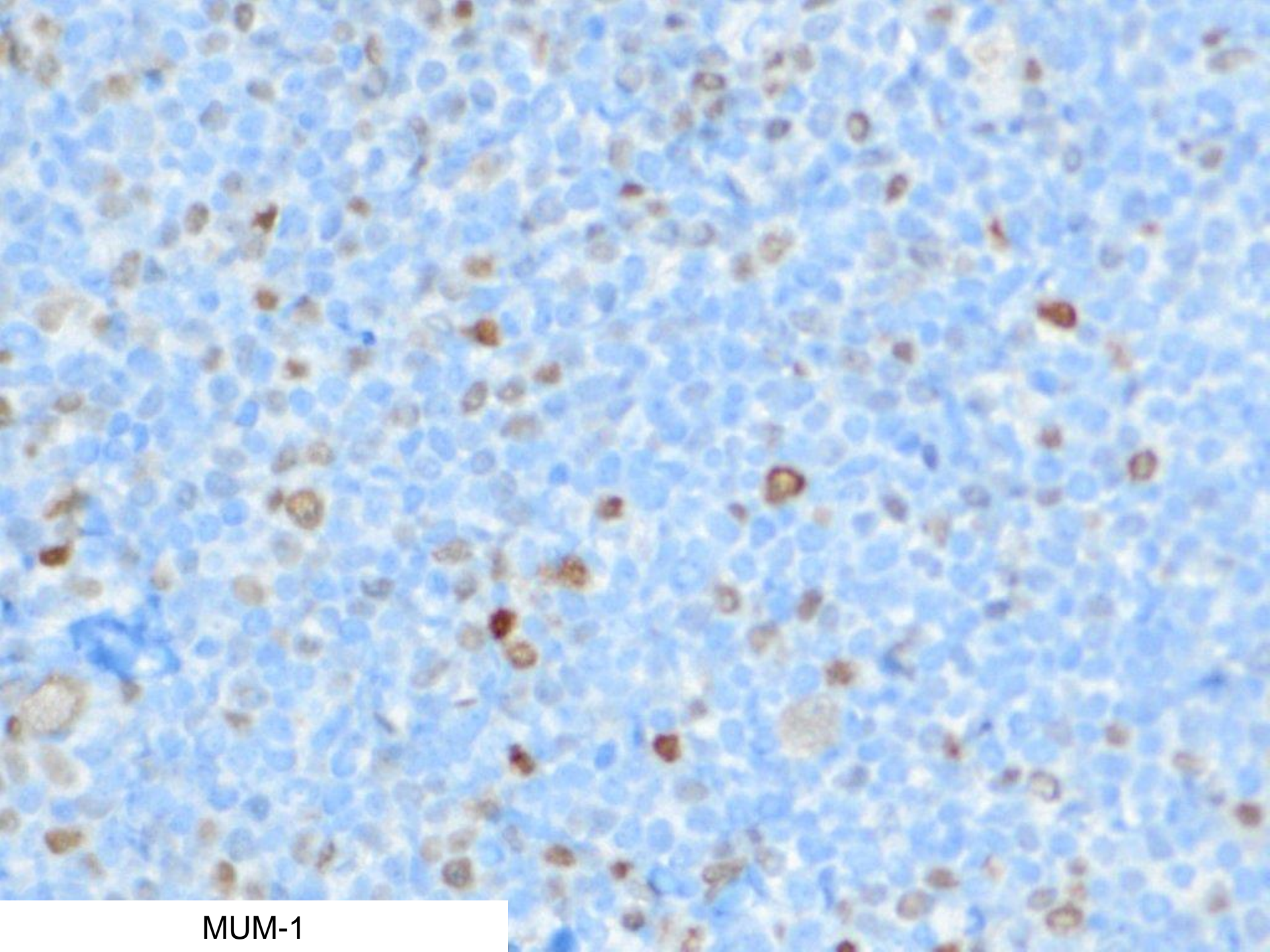
CD21



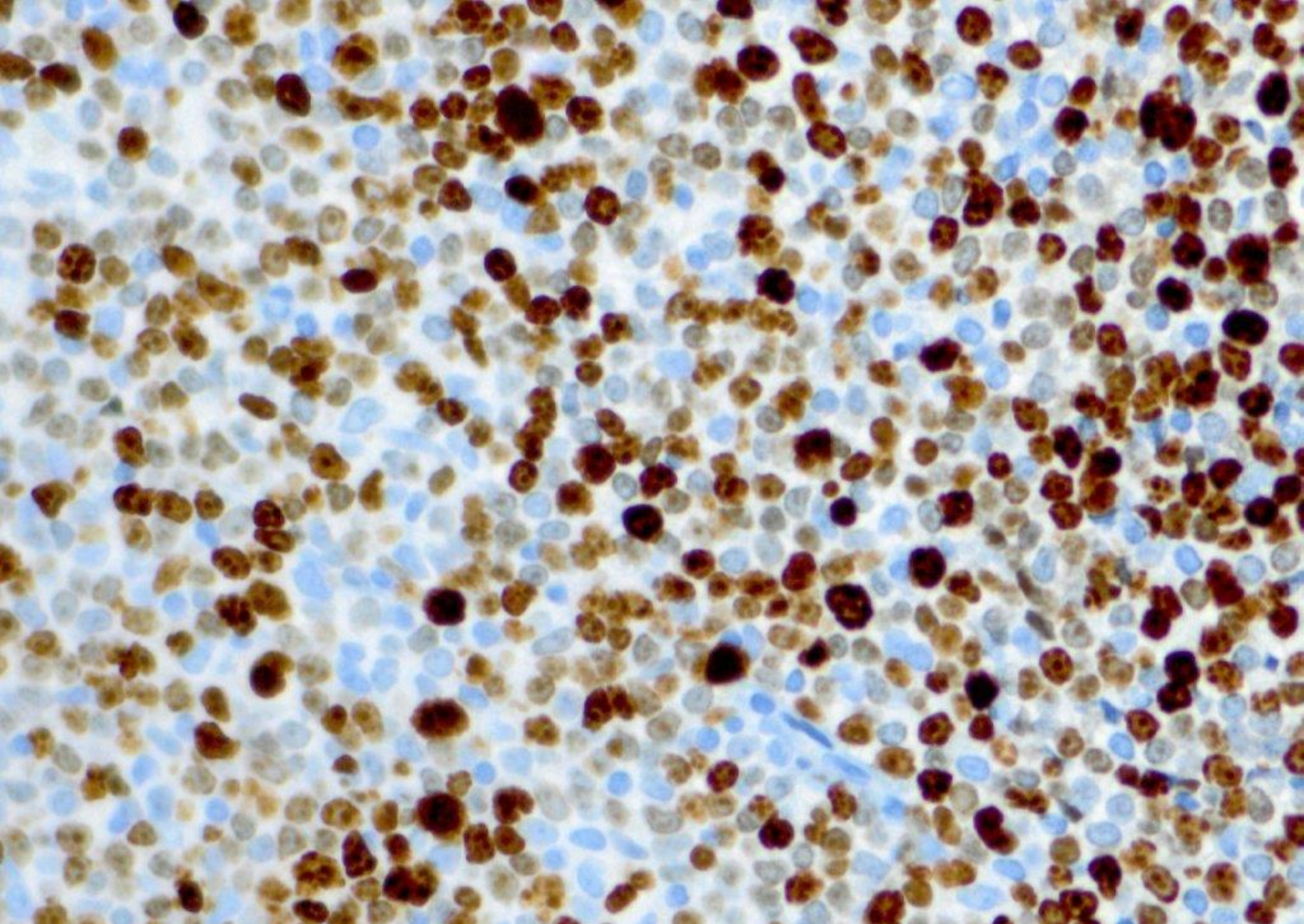
bcl-2



bcl-6

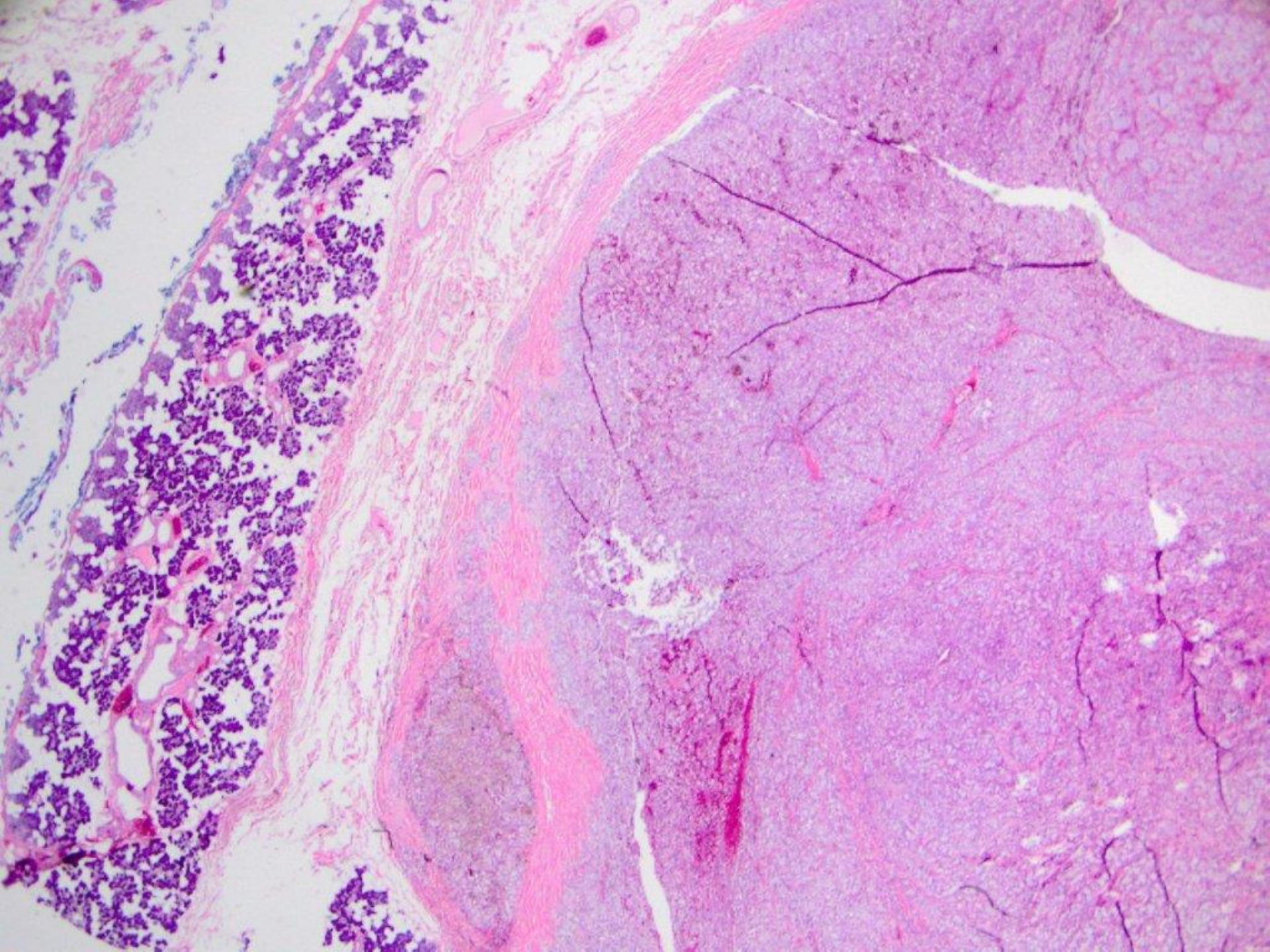


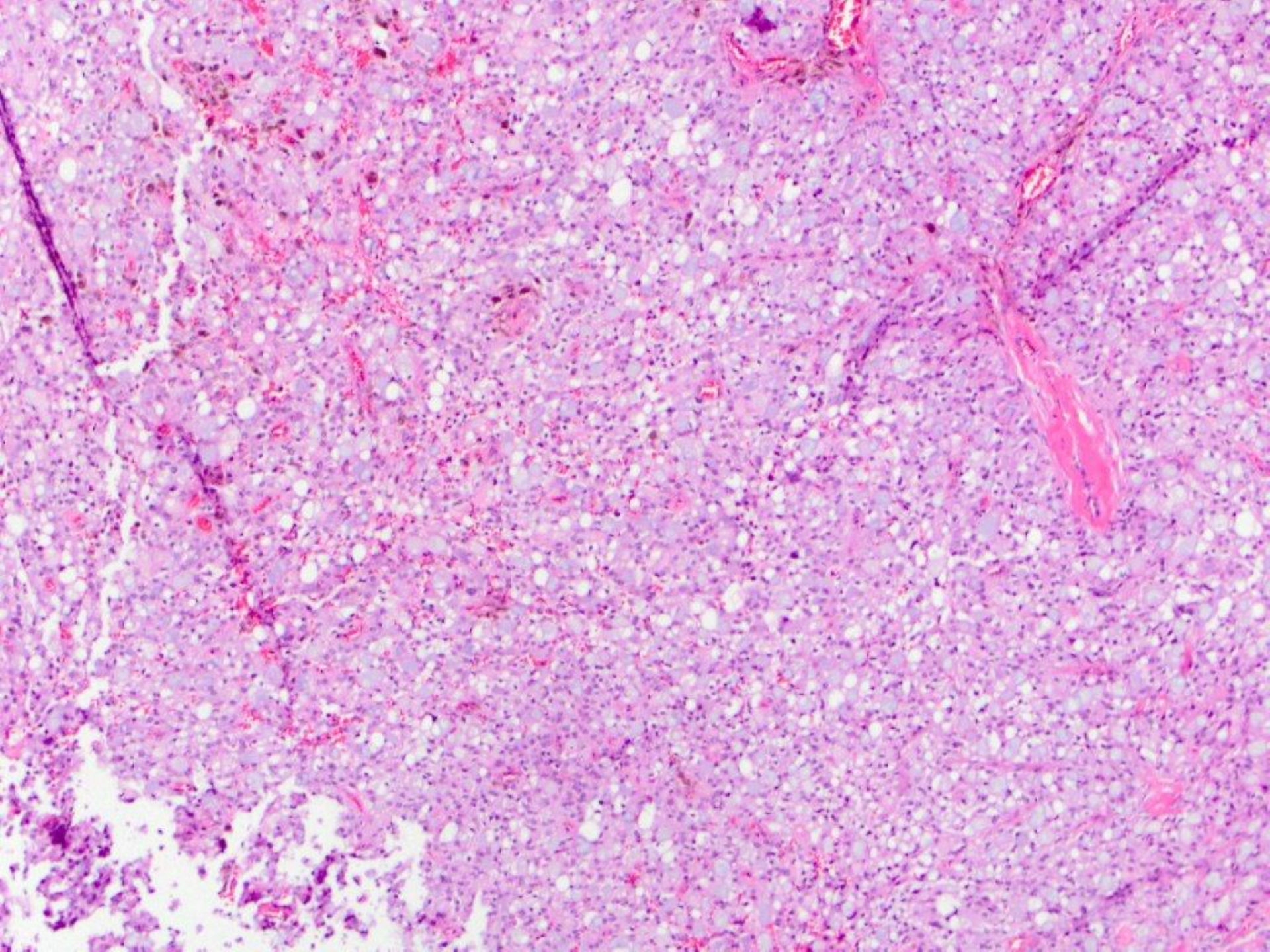
MUM-1

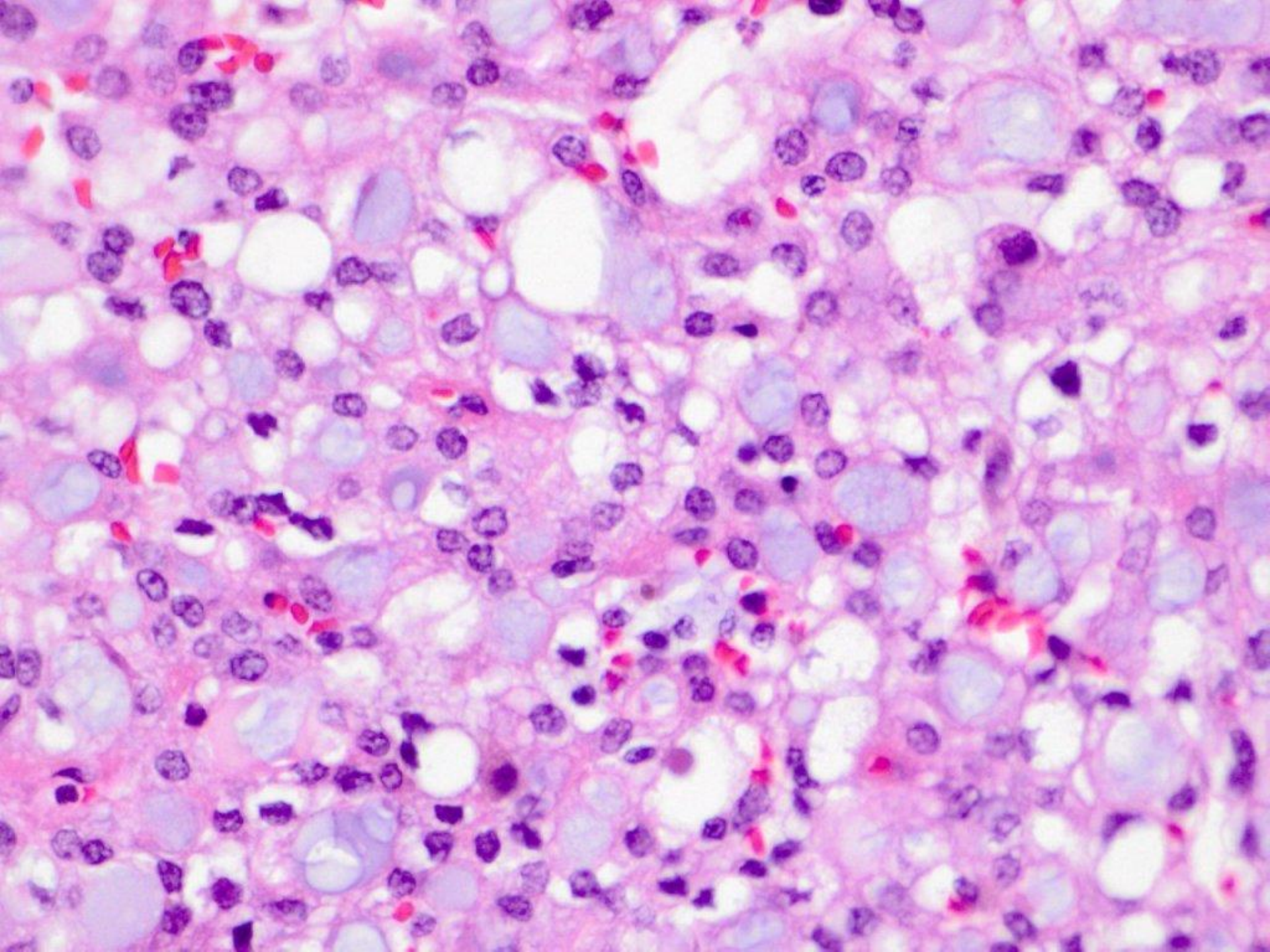


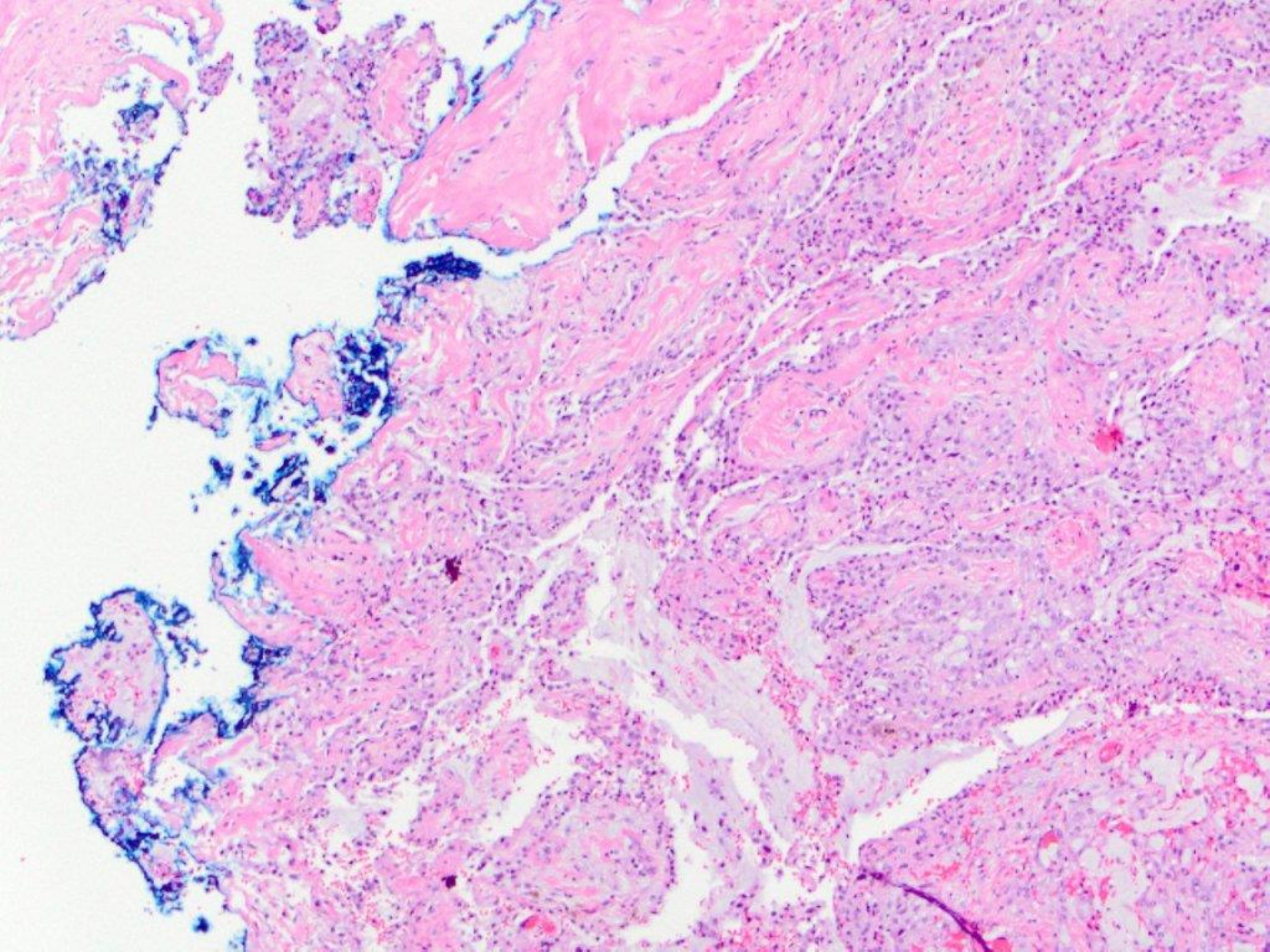
Ki-67

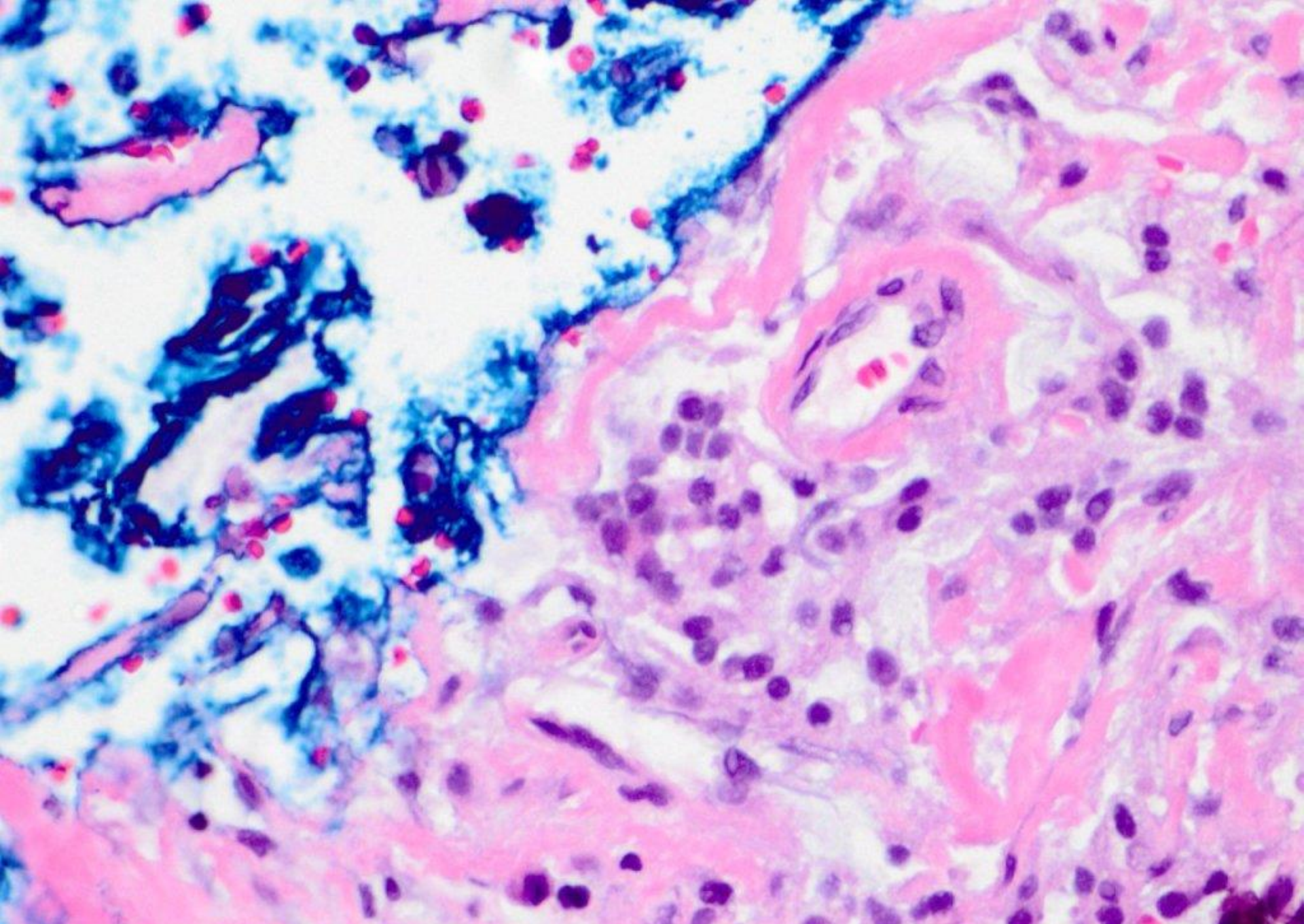
DLBCL











mucoepidermoid carcinoma